

REVIEW ARTICLE

CURRENT CONCEPTS

Current Management of Acute Cutaneous Wounds

Adam J. Singer, M.D., and Alexander B. Dagum, M.D.

IN 2005, 11.8 MILLION WOUNDS WERE TREATED IN EMERGENCY DEPARTMENTS in the United States.¹ More than half a million burns and 7.3 million lacerations are treated annually,² and wounds caused by cutting or piercing instruments are responsible for an additional 2 million outpatient visits each year.³ The number of Americans who are bitten by an animal is estimated to be 4.7 million annually,⁴ and the number of skin tears in the elderly has been estimated at 1.5 million.⁵

From the Department of Emergency Medicine (A.J.S.) and the Division of Plastic and Reconstructive Surgery (A.B.D.), Stony Brook University, Stony Brook, NY. Address reprint requests to Dr. Singer at the Department of Emergency Medicine, Stony Brook University, HSC L4-080, Stony Brook, NY 11794, or at adam.singer@stonybrook.edu.

GENERAL PRINCIPLES OF CARE

In this article we describe our approach to the management of wounds. Wherever possible, our recommendations are based on randomized trials. However, many of the recommendations are based on small, observational studies or expert opinion; thus, we recognize that there may be disagreement with some of our recommendations. Nevertheless, the approach we advise has been shown to be workable and useful.

The primary goal in the management of wounds is to achieve rapid healing with optimal functional and aesthetic results. This is best accomplished by preventing infection and further trauma and by providing an environment that optimizes healing of the wound. All wounds should be thoroughly cleansed with tap water or normal saline.⁶ For heavily contaminated wounds, high-pressure irrigation (>7 psi) can be achieved with the use of a 10-to-50-ml syringe and splatter shield (see the video in the Supplementary Appendix, available with the full text of this article at www.nejm.org).⁷ The patient's tetanus-immunization status should be ascertained, and standard recommendations followed to ensure that the patient is protected against tetanus.

A moist environment for the wound accelerates healing by preventing cellular dehydration and stimulating collagen synthesis and angiogenesis, thus improving cosmesis and reducing pain, the risk of infection, and the costs of care.⁸⁻¹⁰ A moist environment may be created by covering the wound with a topical antimicrobial agent or by applying an occlusive dressing that reduces the loss of fluid through evaporation. Topical antimicrobial agents have been shown to reduce rates of infection of traumatic lacerations,¹¹ although not of wounds caused by elective surgery.¹² Occlusive dressings have also been shown to reduce rates of infection.¹³ Over-the-counter cyanoacrylate liquid bandages are effective for clean, simple wounds.¹⁴ The choice of dressing depends on the cause, size, depth, location, degree of exudation, and level of contamination of the wound, as well as on cost (Table 1). There is no clinically directive evidence to support the choice of one dressing over another.¹⁵ Occlusive dressings are less painful and more convenient for patients and may speed healing, although they are more expensive than topical antibiotics and gauze dressings. In some circumstances, however, the fact that

N Engl J Med 2008;359:1037-46.

Copyright © 2008 Massachusetts Medical Society.

Table 1. Local Therapies for Wounds.

Therapy	Examples	Advantages	Disadvantages	Uses
Topical antimicrobial agents				
Silver sulfadiazine	Silvadene	Wide antimicrobial coverage, painless	Requires frequent dressing changes, delays reepithelialization, stains tissue, may cause allergic reaction, may cause transient leukopenia	Deep burns, weeping burns, heavily contaminated or infected burns
Mafenide acetate	Sulfamylon	Wide antimicrobial coverage, penetrates eschar	Painful, may cause metabolic acidosis, may delay reepithelialization	Deep burns with eschar
Bacitracin		Painless, inexpensive, does not cause staining	Narrower antimicrobial coverage, requires frequent dressing changes, may cause allergic reaction	Facial burns, small burns, abrasions, lacerations, bites
Mupirocin	Bactroban	Painless, good coverage of gram-positive organisms	Expensive, requires frequent dressing changes	Facial burns, abrasions, bites
Triple antibiotic		Wide antimicrobial coverage, inexpensive, painless	Requires frequent dressing changes	Facial burns, small burns, abrasions, lacerations, bites
Nonabsorptive dressings				
Impregnated, non-adherent	Xeroform, Adaptic, Vaseline gauze	Painless, inexpensive	No antimicrobial activity, messy	Superficial burns and abrasions, lacerations
Nonabsorptive polyurethane film	OpSite, Tegaderm	Reduces pain, transparent	Promotes maceration	Minor abrasions, dry superficial burns
Silver-impregnated dressings	Acticoat, Actisorb, Aquacell	Wide antimicrobial coverage, reduces pain	Expensive, needs to be kept moist	Burns
Silicone	Mepitel	Painless, allows seepage of exudate into secondary dressing	Expensive	Burns, deep abrasions
Absorptive dressings				
Hydrocolloids	DuoDERM, Tegaserb	Reduce pain	Malodorous, opaque	Weeping burns, deep abrasions, skin tears
Hydrogels	Aquasorb, Vigilon, Curagel, FlexiGel, Nu-Gel	Rehydrate dry wounds		Weeping burns, deep abrasions, crusted surface exudate
Alginates		Absorb exudate	Require frequent dressing changes, nonadhesive, has been less extensively studied than other dressings	Weeping burns

occlusive dressings need to be changed less often may make them more cost-effective.¹⁶ Wet dressings that promote maceration of the tissue and proliferation of bacteria should be avoided. Prophylactic systemic antibiotics should not be used routinely.¹⁷

ABRASIONS

After the wound has been irrigated and foreign bodies have been removed, abrasions that are limited to the superficial dermis should be treated with a topical antibiotic or an occlusive dress-

ing. Deep abrasions that extend below the dermis (especially if they have a surface area larger than 1 cm² or involve underlying structures) and those that have not healed in 2 weeks may require more advanced care (e.g., grafting), and consultation with a plastic surgeon should be considered.

POST-TRAUMATIC TATTOOING

If particles imbedded in the injured skin are not removed, post-traumatic tattooing (abnormal skin pigmentation due to imbedded foreign particles) will develop. This condition is most commonly seen with injuries from explosions or fire-

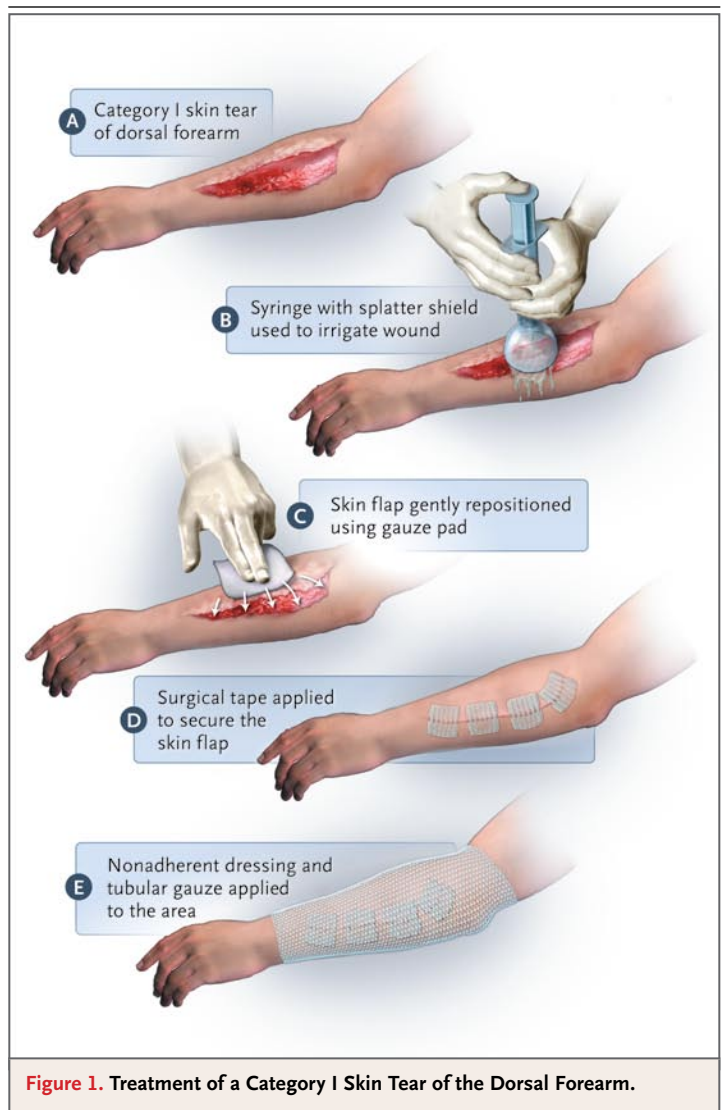
works and “road rash” (abrasion of the skin from contact with a surface containing asphalt, tar, or dirt, with embedding of these particles). Initial treatment consists of the meticulous removal of all particles with standard surgical scrub-brushes. During this procedure, topical lidocaine, local infiltrative anesthetics, or regional anesthetics should be used for abrasions of small-to-moderate size, and systemic opioids or procedural sedation for extensive abrasions. Removal of particles within 24 hours after injury has been shown to have the best cosmetic results.¹⁸ Treatment of established post-traumatic tattooing has had disappointing results and requires referral to a plastic surgeon.

LACERATIONS

The evaluation and management of traumatic lacerations have been reviewed in detail previously.¹⁹ For simple, low-tension lacerations, several new cyanoacrylate topical skin adhesives and surgical tapes are available.^{20,21} They are relatively painless and easy to use, can be applied more rapidly than sutures, and, in the case of adhesives, do not require removal (see video).

SKIN TEARS

Skin tears are particularly common among patients who are receiving long-term corticosteroid therapy and among the elderly, who tend to have fragile skin. For category I tears (without tissue loss), the wound edges can be approximated with surgical tapes, and the area covered with a nonadherent dressing (Fig. 1). In one study, the healing rate of skin tears with the use of this treatment was 66%, as compared with 33% with the use of a thin-film dressing.²² Category II skin tears (partial tissue loss) and category III skin tears (complete tissue loss) can be managed with one of a number of absorbent dressings such as petroleum-based gauzes, hydrogels, foams, hydrocolloids, nylon-impregnated gauzes, and silicone-coated dressings.^{23,24} These dressings usually remain in place for 5 to 7 days and are covered with a secondary absorbent gauze dressing that can be changed daily as needed. Elastic tubular nets should be used to support the underlying dressings. Skin tears of all types that are treated within 8 hours after injury can also be closed with a cyanoacrylate-based topical adhesive.²⁵



PLANTAR PUNCTURE WOUNDS

The rate of superficial infection (i.e., cellulitis) ranges from 2 to 10% among patients who present to the emergency department with plantar puncture wounds.²⁶ Most of the infections are caused by *Staphylococcus aureus* or *Streptococcus pyogenes*. The incidence of osteomyelitis (in most cases caused by pseudomonas), chondritis, and septic arthritis is considerably lower. Puncture wounds in patients who were wearing tennis shoes that were saturated with sweat at the time of injury may be associated with pseudomonas osteomyelitis.

There are no randomized trials that have evaluated the benefits of treating these wounds with prophylactic antibiotics, and there have

been reports of superficial and deep infections even after antibiotic prophylaxis. A prospective, observational study of 63 adults who presented to the emergency department within 24 hours after receiving a plantar puncture wound suggests that cleansing alone may be adequate therapy.²⁷ If this approach is used, close follow-up is recommended, and antibiotics should be administered immediately in patients who have signs and symptoms of infection. If the presence of a foreign body is suspected, computed tomographic imaging or ultrasonography should be used to detect non-radiopaque objects.²⁸ Plain films of the soft tissue are adequate to detect radiopaque objects. Some studies suggest that deep wounds, especially those occurring over the forefoot,²⁹ have an increased likelihood of infection, and patients with such wounds should receive prophylactic antibiotics. Immunocompromised patients and those with foot injuries that occurred while they were wearing tennis shoes that were saturated with sweat should also be considered as candidates for antibiotic prophylaxis. Since most infections are caused by streptococcus or staphylococcus, or occasionally pseudomonas species, antibacterial agents that target these species should be used (e.g., dicloxacillin and ciprofloxacin). Frequent cleansing of the puncture wound and application of a topical antibiotic are also indicated. There is no evidence to support routine coring and high-pressure irrigation of the wound tract.

MAMMALIAN BITES

The risk of infection after dog, cat, and human bites ranges from 3 to 18% for dog bites to 28 to 80% for cat bites.³⁰ Whereas most cat bites are deep puncture wounds, many dog bites cause open lacerations. Large observational studies³¹ and limited clinical trials³² suggest that after high-pressure irrigation of the wound, it is safe to close most bite wounds (even on the extremities) up to 12 hours after injury (healing by primary intention). Puncture wounds and scratches should be allowed to heal by secondary intention. These wounds should be covered with a topical antimicrobial agent and an absorbent dressing. Close follow-up and daily changes of the dressings are required. For large, heavily contaminated lacerations, delayed primary closure, after an observation period of 3 to 5 days (healing by tertiary intention), may be considered. Hu-

man bites that are sustained over the metacarpophalangeal joints (“clenched-fist bites”) are especially prone to infection. These bites require aggressive irrigation and treatment with antibiotics (e.g., amoxicillin-clavulanate) and should not be closed. “Clenched-fist bites” occur as a result of a person punching another person in the mouth and hitting a tooth. The tooth may lacerate the extensor tendon and joint capsule in the hand, inoculating the joint with saliva. Patients may be reluctant to disclose the circumstances that resulted in the injury, and human bites should always be suspected when patients present with lacerations that are located over the metacarpophalangeal joints. These injuries generally require consultation with a specialist.

Although prophylactic antibiotics are widely used for mammalian bites, a systematic review has demonstrated significant reductions in the rates of infection only after bites to the hands (odds ratio, 0.10; 95% confidence interval [CI], 0.01 to 0.86) and human bites (odds ratio, 0.02; 95% CI, 0.00 to 0.33).³³

SUBUNGUAL HEMATOMAS

A subungual hematoma is a painful condition that results from a collection of blood under the fingernail. In the past, for hematomas involving more than 50% of the nail bed, many physicians recommended removal of the nail and repair of any underlying laceration of the nail bed, since the incidence of underlying lacerations was found to be quite high (especially in association with underlying tuft fractures). However, in a study by Seaberg et al., involving 45 patients who presented to the emergency room with subungual hematomas, simple nail trephination resulted in healing without any nail deformities or other complications in all the patients.³⁴ Thus, simple nail trephination with the use of a handheld portable cautery is recommended for most subungual hematomas (see video).³⁴ A prospective study of 52 patients with nail-bed injuries, reported by Roser and Gellman, showed that the outcomes were similar with nail removal and nail trephination, and there were significant cost savings associated with the more conservative care.³⁵ Nail removal should probably be reserved for subungual hematomas that are associated with disruption of the nail or surrounding nail folds. We do not routinely replace the nail plate or put other materials, such as aluminum foil or gauze im-

Table 2. Classification of Burn Severity.*

Criteria and Care	Minor Burn	Moderate Burn	Major Burn
Criteria			
TBSA	<10% in adults, <5% in children or elderly, <2% for full-thickness burn	10–20% in adults, 5–10% in children or elderly, 2–5% for full-thickness burn	>20% in adults, >10% in children and elderly, >5% for full-thickness burn
Other		Low-voltage burn, suspected inhalation injury, circumferential burn, concomitant medical problem predisposing to infection (e.g., diabetes, sickle cell disease)	High-voltage burn, chemical burn, any clinically significant burn to face, eyes, ears, genitalia, or major joints, clinically significant associated injuries (e.g., fracture, other major trauma)
Care	Outpatient management	Admission to a hospital with experience in managing burns	Referral to a burn center

* TBSA denotes total body-surface area. Data are from the American Burn Association³⁷ and the American College of Surgeons.³⁸

pregnated with petrolatum, to separate the nail fold from the nail bed unless there has been a serious injury that requires surgical repair.

BURNS

Burns are dynamic injuries that may progress over the first 2 to 3 days³⁶; therefore, frequent reassessment of the wound is required to ensure optimal management. Many burns are not uniform; the depth of the burn varies from one area to another, further complicating the assessment of the injury. As a rule, therapy should be determined on the basis of the deepest area of the burn.

CLASSIFICATION OF BURNS

Burns are classified on the basis of their depth, surface area, and location; the patient's age; and the presence or absence of coexisting conditions (Table 2). The majority of burns are minor and can be managed by most health care practitioners; more serious burns should be seen by a burn specialist. The criteria for referral to a burn center are listed in Table 2.^{37,38}

First-degree burns are limited to the epidermis and are erythematous and painful. They generally heal within several days. Second-degree burns involve all of the epidermis and part of the underlying dermis and are classified according to the depth of dermal involvement. Superficial second-degree (or partial-thickness) burns involve the upper layers of the dermis and are characterized by clear blisters and weeping (Fig. 2). They are painful and sensitive to touch and blanch

with pressure. These burns usually heal within 2 weeks, with minimal scarring. Deep second-degree burns involve the deeper layers of the dermis and are often difficult to distinguish from third-degree, or full-thickness, burns, which involve the entire dermis. Deep dermal burns are characterized by hemorrhagic blisters and are covered with a layer of white or red injured dermis that does not blanch (Fig. 2). These burns usually do not heal for at least 3 weeks and often result in hypertrophic scarring and contractures, especially in children. It is very important to distinguish between superficial second-degree burns and deeper burns (deep partial-thickness and full-thickness burns). Full-thickness burns may be dark brown or tan and have a leathery texture that is insensitive to touch (Fig. 2). Circumferential burns (burns that completely encircle a limb, the neck, or the torso) can compromise perfusion, and it may be necessary to relieve the pressure by means of an escharotomy, in which an incision is made over the lateral and medial aspects of the involved areas down to the subcutaneous tissue (Fig. 3). The depth of a burn is often difficult to assess immediately after injury and is often underestimated. The true depth of the burn becomes more obvious with time; therefore, careful surveillance of the wound and reassessment of the treatment are necessary. When in doubt, early consultation with a burn specialist is recommended.

The size of a burn is described by an estimation of the percentage of the total body-surface area that has sustained second- or third-degree

burns. The area may be estimated with the use of standardized body charts, such as the Lund-Browder chart for children,³⁹ which accounts for age-related changes in surface area, and the “Rule of Nines” for patients 10 years of age or older. The Rule of Nines method assigns 9% of the total body-surface area to the head and neck and 9% to each upper extremity and assigns 18% each to the anterior trunk, the posterior trunk, and the lower extremities; the remaining 1% is assigned to the genitalia. In the case of small burns, the area can be estimated by comparing the size of the burn to the palm of the patient’s hand, which represents approximately 1% of the total body-surface area.⁴⁰ Errors in estimating the size of the burn, often resulting in overestimation, are common when physicians guess the size instead of using standardized body charts.⁴¹

COOLING OF BURNS

Cooling of burns with the use of cold (15 to 25°C) tap water within 30 minutes after injury has been shown to reduce the pain, the depth and extent of the injury, the need for surgical excision of the burn, scarring, and mortality.⁴²⁻⁴⁵ The use of ice or ice water may increase tissue injury and should be avoided.^{45,46} Concern that cooling of large burns may result in hypothermia has been based on a single study in small animals with extensive burns.⁴² In contrast, cooling of uninjured subjects with a commercially available cooling blanket at room temperature did not reduce core body temperature,⁴⁷ a finding that challenges the recommendation to avoid cooling large burns. Cooling of burns should continue until the pain is substantially reduced or resolves.

MANAGEMENT OF BLISTERS

The debate regarding the removal of burn blisters has been fueled by conflicting data regarding the *in vitro* effects of blister fluid. Two clinical trials involving patients and volunteers with superficial burns demonstrated that intact blisters healed faster and were less likely to become infected than blisters that were ruptured.^{48,49} These results are supported by a study in pigs, in which removal of the necrotic epidermis slowed reepithelialization and increased the rate of infection and scarring.⁵⁰ Blisters larger than 3 cm in diameter and those over mobile areas usually rupture spontaneously and may be aspirated under sterile conditions.⁴⁸ When blisters rupture,

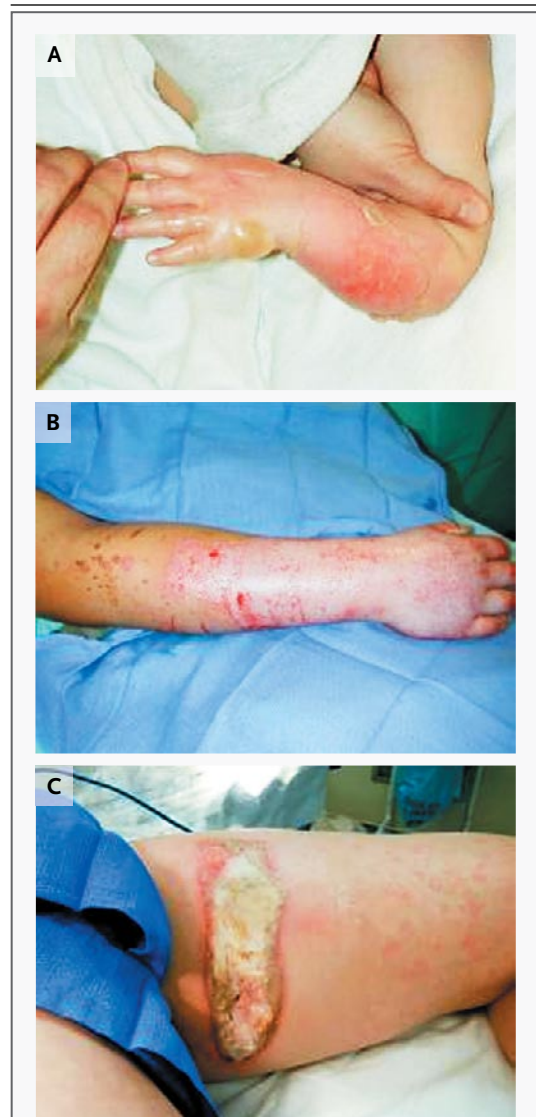

Figure 2. Determination of Burn Depth.

A superficial second-degree burn is shown in Panel A, a deep second-degree burn in Panel B, and a third-degree burn in Panel C.

the wound should be washed with soap and water, and the nonadherent necrotic epidermis carefully removed. In order to relieve the pain while the burn is being thoroughly cleansed, the patient will often require analgesia with oral or parenteral opioids.

LOCAL THERAPY FOR BURNS

Although first-degree burns do not require any specific therapy, topical nonsteroidal antiinflammatory drugs or aloe vera may be used to reduce

the pain.^{51,52} Deep second-degree burns and third-degree burns should be covered with a topical antimicrobial agent, and the patient referred to a burn specialist for consultation regarding the need for excision and grafting. Routine use of systemic antibiotics is not supported by the evidence.⁵³ Superficial second-degree burns should be treated with a topical antimicrobial agent or an absorptive occlusive dressing. Studies suggest that occlusive dressings are more convenient and less painful than treatment with topical antimicrobial agents and result in more rapid healing.⁵⁴ The optimal treatment for heavily contaminated or infected burns and those with a large amount of exudate is application of topical antimicrobial agents and absorbent gauze dressings.

Traditional topical antimicrobial agents that contain silver, such as silver sulfadiazine, confer wide antimicrobial coverage and are most useful for deep second-degree burns and third-degree burns. However, the use of these antimicrobial agents is associated with cellular toxicity and delayed healing.⁵⁵ Synthetic dressings that reduce the cytotoxic effects of silver by slowly releasing it in small amounts are now available. They are more effective than silver sulfadiazine in reducing pain and improving healing⁵⁶ and may be more cost-effective.¹⁶ A large number of topical antimicrobial agents that do not contain silver are also available (e.g., bacitracin and mupirocin); however, there is little evidence that demonstrates the superiority of one agent over the others.

A large number of synthetic and biologic occlusive dressings have been evaluated for the local management of burns.⁵⁷ Absorptive hydrocolloid dressings can be used for weeping burns, although they tend to become malodorous. As compared with silver sulfadiazine, these dressings have been shown to result in less pain, better acceptance and compliance, and more pleasing cosmetic results in patients with superficial partial-thickness burns.⁵⁸ They are also as effective as and less expensive than collagen-based dressings.⁵⁹ The polyurethane films are not recommended, since they do not absorb exudate. A silicone mesh dressing that adheres gently to the wound bed and allows wound exudate to escape onto a secondary dressing is also available and results in faster healing than treatment with silver sulfadiazine.⁶⁰ Biologic dressings based on collagen or skin cells should be

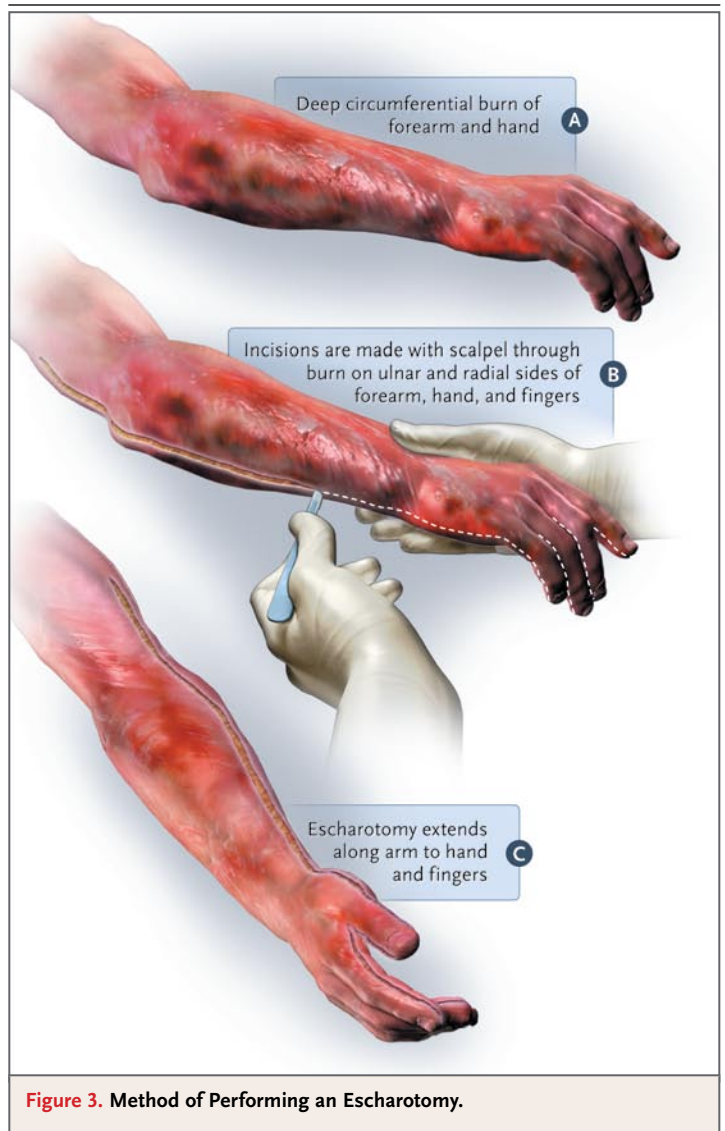


Figure 3. Method of Performing an Escharotomy.

reserved for deep burns and should be applied by a burn specialist.⁶¹ The American Burn Association has published guidelines that address the management of burns.¹⁵ However, these guidelines are very limited in scope and do not address cooling, management of blisters, or choice of burn dressings. Further research is needed so that more comprehensive guidelines can be established for the treatment of burns.

CHEMICAL BURNS

Chemical burns cause tissue injury through the interaction of the chemical agent with the tissue. Initial treatment consists of copious water lavage commencing at the scene and removal of any

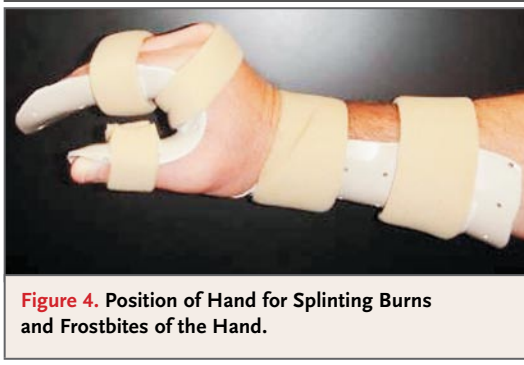

Figure 4. Position of Hand for Splinting Burns and Frostbites of the Hand.

particles.⁶² The important exception to the treatment of a chemical burn with water lavage involves injury from the elemental metals (i.e., lithium, sodium, magnesium, and potassium), which spontaneously ignite with water. Exposure to hydrofluoric acid, which is used in etching and rust removal, leads to intense pain and tissue damage.^{62,63} Treatment includes copious irrigation followed by the application of calcium gluconate gel or subcutaneous injection of calcium gluconate, with the goal of relieving the pain. A burn from hydrofluoric acid that involves more than 5% of total body-surface area, or more than 1% of total body-surface area if the concentration of hydrofluoric acid is greater than 50%, requires

admission to the hospital for electrocardiographic monitoring and serial measurements of calcium levels, since life-threatening arrhythmias and hypocalcemia can occur. The patient should be referred to a burn specialist, since immediate excision of the wound may be necessary in the case of hypocalcemia that is unresponsive to intra-arterial or intravenous calcium gluconate.^{62,63}

FROSTBITE

Frostbite occurs when exposure to cold results in the freezing of tissue. It usually affects the most exposed appendages — that is, fingers, toes, nose, and ears. Initial treatment consists of rapid rewarming over a period of 20 minutes in water that is at a temperature of 40 to 42°C.⁶⁴ Opioids are used to control pain. Massaging the area is not recommended, since it may increase tissue damage. The appearance of the skin after rewarming and over the next 24 to 48 hours is the main clinical factor that is used to determine the level and extent of the injury. The use of radioimaging with technetium-99m at 1 week is helpful in predicting the ultimate level of tissue injury and the extent of amputation that may be required.⁶⁵ Frostbite is classified in the same way as burns (i.e., according to the size and depth of the injury) 24 to 48 hours after rewarming. Be-

Table 3. Common Problems and Potential Solutions in Wound Management.

Type of Wound	Problem	Potential Solutions
Abrasion	Post-traumatic tattooing	Aggressive scrubbing and removal of all foreign material
	Damage to underlying structures	Meticulous examination
Laceration	Missed foreign bodies	Careful exploration with optimal lighting, adequate hemostasis, advanced imaging, as needed
	Missed tendon injuries	Careful exploration, testing of passive and active range of motion, wound visualization through full range of motion
	Missed digital-nerve injuries	Careful sensory examination, assessment of two-point discrimination, ascertainment of Tinel’s sign at injury site
	Infections	Thorough irrigation, close follow-up, judicious use of prophylactic systemic antibiotics, use of topical antibiotics, secondary or delayed primary closure for highly contaminated wounds
	Missed diagnosis of human bite	Observation of laceration over metacarpophalangeal joint, ascertainment of pain on applying pressure to the joint, exploration and assessment of extensor tendon through full range of motion and joint capsule for laceration
Burn	Underestimation of depth of injury	Frequent reassessments, follow-up by burn specialist if burn does not heal or becomes infected
	Overestimation of extent of injury	Use of standardized charts or patient’s palm size
	Compartment syndromes	Elevation, close clinical follow-up and serial Doppler ultrasonography, escharotomy for circumferential third-degree burns
	Scarring and contractures	Early referral for excision of deep burns or burns that have not healed by 2 wk
	Overestimation of degree of injury from frostbite	Reassessment the day after rewarming

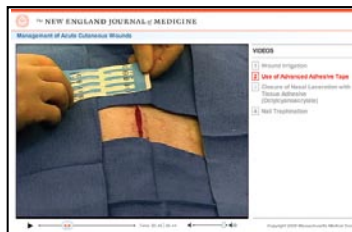fore rewarming, all degrees of frostbite usually look the same. Other than rapid rewarming, there are no unified treatment protocols for frostbite. General principles for treatment include splinting and elevation of the injured area (Fig. 4). Treatment with ibuprofen, 400 mg twice daily, is recommended to decrease the levels of prostaglandin and thromboxane, since elevated levels lead to vasoconstriction and platelet aggregation, resulting in progressive tissue injury. Management of the blisters is controversial; some physicians recommend routine débridement and application of aloe vera because of the high concentrations of prostaglandin $F_{2\alpha}$ and thromboxane B_2 .⁶⁶ We do not recommend routine removal of blisters because of the risk of desiccation; we prefer sterile aspiration of tense blisters that are larger than 3 cm in diameter.⁶⁷ Recently, it has been shown that tissue plasminogen activator given intravenously or intraarterially within 24 hours after injury and within 6 hours after rewarming significantly decreases the extent and level of amputation.^{68,69} Other treatments have included sympathectomies, hyperbaric oxygen, and pentoxifylline.⁷⁰ In general, the treatment remains conservative until the wound is completely healed or clearly demarcated. This process usually takes more than 3 weeks, at

which time final débridement and grafting, flap coverage, or amputation is performed, as needed.

SUMMARY

Many types of cutaneous wounds are managed by a variety of health care practitioners in multiple clinical settings. Wound irrigation, débridement, protection from further trauma and bacterial contamination, creation of a moist wound environment, and judicious use of antibiotics (when indicated) will help achieve optimal outcomes. Table 3 lists common problems and potential solutions in the acute management of wounds.

Dr. Singer reports receiving consulting and lecture fees and grant support from Closure Medical and Ethicon. No other potential conflict of interest relevant to this article was reported.



A video showing management of acute cutaneous wounds is available at www.nejm.org.

REFERENCES

- Nawar EW, Niska RW, Xu J. National Hospital Ambulatory Medical Care Survey: 2005 emergency department summary. Advance data from vital health statistics. No. 386. Hyattsville, MD: National Center for Health Statistics, 2007.
- Singer AJ, Thode HC, Hollander JE. National trends in ED lacerations between 1992 and 2002. *Am J Emerg Med* 2006; 24:183-8.
- Hing E, Cherry DK, Woodwell DA. National Ambulatory Medical Care Survey: 2004 summary. Advance data from vital and health statistics. No. 374. Hyattsville, MD: National Center for Health Statistics, 2006.
- Sacks JJ, Kresnow M, Houston B. Dog bites: how big a problem? *Inj Prev* 1996;2: 52-4.
- Malone ML, Rozario N, Gaviniski M, Goodwin J. The epidemiology of skin tears in the institutionalized elderly. *J Am Geriatr Soc* 1991;39:591-5.
- Chatterjee JS. A critical review of irrigation technique in acute wounds. *Int Wound J* 2005;2:258-65.
- Mittra ES, Singer AJ, Bluestein D, Hollander JE. Simulated wound irrigation impact pressures. *Israeli J Emerg Med* 2003; 3:9-16.
- Field FK, Kerstein MD. Overview of wound healing in moist environment. *Am J Surg* 1994;167:Suppl 1A:2S-6S.
- Winter GD. Formation of the scab and the rate of epitheliation of superficial wounds in the skin of the young domestic pig. *Nature* 1962;193:293-4.
- Singh A, Halder S, Menon GR, et al. Meta-analysis of randomized controlled trials on hydrocolloid occlusive dressings versus conventional gauze in healing chronic wounds. *Asian J Surg* 2004;27:326-32.
- Dire DJ, Coppola M, Dwyer DA, et al. A prospective evaluation of topical antibiotics for preventing infections in uncomplicated soft-tissue wounds repaired in the ED. *Acad Emerg Med* 1995;2:4-10.
- Smack DP, Harrington AC, Dunn C, et al. Infection and allergy incidence in ambulatory surgery patients using white petrolatum vs bacitracin ointment: a randomized controlled trial. *JAMA* 1996;276: 972-7.
- Hutchinson JJ. Prevalence of wound infection under occlusive dressings: a collective survey of reported research. *Wounds* 1989;1:123-33.
- Eaglstain WH, Sullivan TP, Giordana PA, Miskin BM. A liquid adhesive bandage for the treatment of minor cuts and abrasions. *Dermatol Surg* 2002;28:263-7.
- American Burn Association. Practice guidelines for burn care. *J Burn Care Rehabil* 2001;22:Suppl:S1-S69.
- Cuttle L, Naidu S, Mill J, Hoskins W, Das K, Kimble RM. A retrospective cohort study of Acticoat versus Silvazine in paediatric population. *Burns* 2007;33:701-7.
- Cummings P, Del Beccaro MA. Antibiotics to prevent infection of simple wounds: a meta-analysis of randomized studies. *Am J Emerg Med* 1995;13:396-400.
- Böhler K, Müller E, Huber-Spitz V, et al. Treatment of traumatic tattoos with various sterile brushes. *J Am Acad Dermatol* 1992;26:749-53.
- Singer AJ, Hollander JE, Quinn JV. Evaluation and management of traumatic lacerations. *N Engl J Med* 1997;337:1142-8.
- Singer AJ, Quinn JV, Clark RE, Hollander JE. Closure of lacerations and incisions with octylcyanoacrylate: a multicenter randomized clinical trial. *Surgery* 2002;131:270-6.
- Kuo F, Lee D, Rogers GS. Prospective, randomized, blinded study of a new wound closure film versus cutaneous suture for surgical wound closure. *Dermatol Surg* 2006;32:676-81.
- Non-occlusive dressings better for skin tears in the elderly. *Aust Nurs J* 1998;5:38.

23. Edwards H, Gaskill D, Nash R. Treating skin tears in nursing home residents: a pilot study comparing four types of dressings. *Int J Nurs Pract* 1998;4:25-32.
24. Meuleneire F. Using a soft silicone-coated net dressing to manage skin tears. *J Wound Care* 2002;11:365-9.
25. Milne CT, Corbett LQ. A new option in the treatment of skin tears for the institutionalized resident: formulated 2-octylcyanoacrylate topical bandage. *Geriatr Nurs* 2005;26:321-5.
26. Chachad S, Kamat D. Management of plantar puncture wounds in children. *Clin Pediatr (Phila)* 2004;43:213-6.
27. Schwab RA, Powers RD. Conservative therapy of plantar puncture wounds. *J Emerg Med* 1995;13:291-5.
28. Fessell DP, van Holsbeeck MT. Foot and ankle radiography. *Radiol Clin North Am* 1999;37:831-58.
29. Patzakis MJ, Wilkins J, Brien WW, Carter VS. Wound site as a predictor of complications following deep nail punctures to the foot. *West J Med* 1989;150:545-7.
30. Talan DA, Citron DM, Abrahamian FM, Moran GJ, Goldstein EJC. Bacteriologic analysis of infected dog and cat bites. *N Engl J Med* 1999;340:85-92.
31. Chen E, Hornig S, Shepherd SM, Hollander JE. Primary closure of mammalian bites. *Acad Emerg Med* 2000;7:157-61.
32. Maimaris C, Quinton DN. Dog-bite lacerations: a controlled trial of primary wound closure. *Arch Emerg Med* 1988;5:156-61.
33. Medeiros I, Saconato H. Antibiotic prophylaxis for mammalian bites. *Cochrane Database Syst Rev* 2001;2:CD001738.
34. Seaberg DC, Angelos WJ, Paris PM. Treatment of subungual hematomas with nail trephination: a prospective study. *Am J Emerg Med* 1991;9:209-10.
35. Roser SE, Gellman H. Comparison of nail bed repair versus nail trephination for subungual hematomas in children. *J Hand Surg [Am]* 1999;24:1166-70.
36. Singh V, Devgan L, Bhat S, Milner SM. The pathogenesis of burn wound conversion. *Ann Plast Surg* 2007;59:109-15.
37. Hospital and prehospital resources for optimal care of patients with burn injury: guidelines for development and operation of burn centers. *J Burn Care Rehabil* 1990;11:98-104.
38. Committee on Trauma. Resources for optimal care of the injured patient, 1999: guidelines for the operations of burn units. Chicago: American College of Surgeons, 1998.
39. Lund CC, Browder NC. The estimate of areas of burns. *Surg Gynecol Obstet* 1944;79:352-8.
40. Sheridan RL, Petras L, Basha G, et al. Planimetry study of the percent of body surface represented by the hand and palm: sizing irregular burns is more accurately done with the palm. *J Burn Care Rehabil* 1995;16:605-6.
41. Hammond JS, Ward CG. Transfers from emergency room to burn center: errors in burn size estimate. *J Trauma* 1987;27:1161-5.
42. Ofeigsson OJ. Water cooling: first-aid treatment for scalds and burns. *Surgery* 1965;57:391-400.
43. Nguyen NL, Gun RT, Sparnon AL, Ryan P. The importance of immediate cooling — a case series of childhood burns in Vietnam. *Burns* 2002;28:173-6.
44. Jandera V, Hudson DA, de Wet PM, Innes PM, Rode H. Cooling the burn: evaluation of different modalities. *Burns* 2000;26:265-70.
45. Venter TH, Karpelowsky JS, Rode H. Cooling of the burn: the ideal temperature of the coolant. *Burns* 2007;33:917-22.
46. Purdue GF, Layton TR, Copeland CE. Cold injury complicating burn therapy. *J Trauma* 1985;25:167-8.
47. Singer AJ, Friedman B, Modi P, Soroff HS. Effects of a commercially available burn-cooling blanket on core temperatures in volunteers. *Acad Emerg Med* 2006;13:686-90.
48. Swain AH, Azadian BS, Wakeley CJ, Shakespeare PG. Management of blisters in minor burns. *BMJ* 1987;295:181.
49. Gimbel NS, Kapetansky DI, Weissman F, Pinkus HKB. A study of epithelialization in blistered burns. *AMA Arch Surg* 1957;74:800-3.
50. Singer AJ, Thode HC Jr, McClain SA. The effects of epidermal débridement of partial-thickness burns on infection and reepithelialization in swine. *Acad Emerg Med* 2000;7:114-9.
51. Magnette J, Kienzler JL, Aleksandrova E, et al. The efficacy and safety of low-dose diclofenac sodium 0.1% gel for the symptomatic relief of pain and erythema associated with superficial natural sunburn. *Eur J Dermatol* 2004;14:238-46.
52. Maenthaisong R, Chaiyakunapruk N, Niruntraporn S, Kongkaew C. The efficacy of aloe vera used for burn wound healing: a systematic review. *Burns* 2007;33:713-8.
53. Uguro AO, Atoyebi OA, Oyeyin JO, Swoemimo GOA. An evaluation of the role of systemic antibiotic prophylaxis in the control of burn wound infection at the Lagos University Teaching Hospital. *Burns* 2004;30:43-8.
54. Eaglstein WH. Experiences with bio-synthetic dressings. *J Am Acad Dermatol* 1985;12:434-40.
55. Fraser JF, Cuttle L, Kempf M, Kimble RM. Cytotoxicity of topical antimicrobial used in burn wounds in Australasia. *ANZ J Surg* 2004;74:139-42.
56. Tredget EE, Shankowsky HA, Groeneveld A, Burrell R. A matched-pair, randomized study evaluating the efficacy and safety of Acticoat silver-coated dressing for the treatment of burn wounds. *J Burn Care Rehabil* 1998;19:531-7.
57. Atiyeh BS, Hayek SN, Gunn SW. New technologies for burn wound closure and healing — review of the literature. *Burns* 2005;31:944-56.
58. Afilalo M, Dankoff J, Guttman A, Lloyd J. DuoDERM hydroactive dressing versus silver sulfadiazine/Bactigras in the emergency treatment of partial skin thickness burns. *Burns* 1992;18:313-6.
59. Cassidy C, St Peter SD, Lacey S, et al. Biobrane versus Duoderm for the treatment of intermediate thickness burns in children: a prospective, randomized trial. *Burns* 2005;31:890-3.
60. Gotschall CS, Morrison MI, Eichelberger MR. Prospective, randomized study of the efficacy of Mepitel on children with partial-thickness scalds. *J Burn Care Rehabil* 1998;19:279-83.
61. Pham C, Greenwood J, Cleland H, Woodruff P, Maddern G. Bioengineered skin substitutes for the management of burns: a systemic review. *Burns* 2007;33:946-57.
62. Kirkpatrick JJ, Burd DA. An algorithmic approach to the treatment of hydrofluoric acid burns. *Burns* 1995;21:495-9.
63. Dünser MW, Ohlbauer M, Rieder J, et al. Critical care management of major hydrofluoric acid burns: a case report, review of the literature, and recommendations for therapy. *Burns* 2004;30:391-8.
64. McCauley RL, Hing DN, Robson MC, Heggors JP. Frostbite injuries: a rational approach based on the pathophysiology. *J Trauma* 1983;23:143-7.
65. Cauchy E, Marsigny B, Allamel G, Verhellen R, Chetaille E. The value of technetium 99 scintigraphy in the prognosis of amputation in severe frostbite injuries of the extremities: a retrospective study of 92 severe frostbite injuries. *J Hand Surg [Am]* 2000;25:969-78.
66. Robson MC, Heggors JP. Evaluation of hand frostbite blister fluid as a clue to pathogenesis. *J Hand Surg [Am]* 1981;6:43-7.
67. Biem J, Koehncke N, Classen D, Dosman J. Out of the cold: management of hypothermia and frostbite. *CMAJ* 2003;168:305-11.
68. Bruen KJ, Ballard JR, Morris SE, Cochran A, Edelman LS, Saffle JR. Reduction of the incidence of amputation in frostbite injury with thrombolytic therapy. *Arch Surg* 2007;142:546-51.
69. Twomey JA, Peltier GL, Zera RT. An open-label study to evaluate the safety and efficacy of tissue plasminogen activator in treatment of severe frostbite. *J Trauma* 2005;59:1350-5.
70. Murphy JV, Banwell PE, Roberts AH, McGrouther DA. Frostbite: pathogenesis and treatment. *J Trauma* 2000;48:171-8.