


THOTTATHIL GOPAN, MD

 Department of Endocrinology, Diabetes,
and Metabolism, Cleveland Clinic

ERICK REMER, MD

Department of Radiology, Cleveland Clinic

AMIR H. HAMRAHIAN, MD

 Department of Endocrinology, Diabetes,
and Metabolism, Cleveland Clinic

Evaluating and managing adrenal incidentalomas

■ ABSTRACT

Adrenal masses that are found incidentally should be evaluated with both imaging and hormonal studies. The attenuation coefficient on noncontrast computed tomography (CT), expressed in Hounsfield units (HU), is better than tumor size in differentiating adrenal adenomas and hyperplastic lesions from nonadenomas. All patients should undergo hormonal evaluation for Cushing syndrome and pheochromocytoma. Those with hypertension should also be evaluated for hyperaldosteronism.

■ KEY POINTS

Adrenal masses are detected incidentally in up to 5% of patients undergoing abdominal imaging studies. Up to one in five are functional.

Once the radiologic characteristics of an adrenal mass have been taken into consideration, a 6-cm tumor size is a reasonable threshold for surgical resection.

A noncontrast CT attenuation coefficient of less than 10 HU reliably rules out adrenal metastasis and adrenal cortical carcinoma.

There is no good evidence to support continuing radiologic surveillance if the size of the tumor does not increase in 6 to 12 months.

Patients with adrenal tumors with a noncontrast CT attenuation coefficient of 10 HU or less should have a yearly evaluation for hormonal hypersecretion. The optimal duration of follow-up is not known, but the incidence of hypersecretion may plateau after 5 years.

A 75-YEAR-OLD African American man is referred for evaluation of a nodule in the left adrenal gland, which was discovered on computed tomography (CT) without contrast, performed as part of a workup for anemia. The nodule measures 2.1 by 1.3 cm; no other abnormalities are visible. The patient has a history of hypertension that is well controlled with medications. He does not smoke or drink alcohol, and his family history is unremarkable. He reports no symptoms.

Physical examination reveals nothing remarkable, with no evidence of Cushing syndrome. His blood pressure is 140/70 mm Hg, serum potassium concentration 3.6 mmol/L, and fasting plasma glucose 90 mg/dL.

How should this patient be further evaluated?

■ ADRENAL INCIDENTALOMAS: A CLINICAL QUANDARY

Widespread use of imaging tests such as abdominal ultrasonography, CT, and magnetic resonance imaging (MRI) is creating the clinical quandary of what to do about adrenal incidentalomas—masses of 1 cm or larger on the adrenal glands discovered serendipitously on imaging in patients with no symptoms or clinical evidence of adrenal disease. (This definition excludes findings in patients undergoing imaging procedures as part of a cancer workup or staging.)

How can one determine if these lesions are clinically benign or need treatment?

■ BECOMING EVER MORE COMMON

The prevalence of adrenal incidentalomas ranges from 1.4% to 8.7%, increasing with age.¹⁻⁴ Adrenal incidentalomas are found in

TABLE 1

Causes and prevalence of adrenal incidentalomas

CAUSE	PREVALENCE (%)
Adrenal cortical tumors	
Adenoma	36–94
Nodular hyperplasia	7–17
Adrenocortical carcinoma	1.2–11
Adrenal medullary tumors	
Pheochromocytoma	1.5–11
Other adrenal tumors	
Myelolipoma	7–15
Lipoma	0–11
Cysts and pseudocysts	4–22
Hematoma and hemorrhage	0–4
Infections, granulomas	Rare
Metastases	0–21

DATA FROM NATIONAL INSTITUTES OF HEALTH STATE-OF-THE-SCIENCE CONFERENCE STATEMENT. MANAGEMENT OF THE CLINICALLY INAPPARENT ADRENAL MASS (INCIDENTALOMA). FEBRUARY 4–6, 2002. [HTTP://CONSENSUS.NIH.GOV/TA/021/021_STATEMENT.HTM](http://consensus.nih.gov/ta/021/021_STATEMENT.HTM); AND KLOOS RT, GROSS MD, FRANCIS JR, KOROBKIN M, SHAPIRO B. INCIDENTALY DISCOVERED ADRENAL MASSES. ENDOCR REV 1995; 16:460–484.

up to 5% of patients undergoing CT of the abdomen,^{3–5} and as imaging techniques improve, they can be expected to be discovered even more frequently.

TABLE 1 lists the most common histologic types of adrenal incidentalomas.^{4–6} The probability of a specific type varies with the clinical picture. For example, in patients with cancer, up to 75% of adrenal incidentalomas are metastatic lesions, but in patients with no history of cancer two thirds are benign.⁷

■ TWO IMPORTANT QUESTIONS

In evaluating an adrenal incidentaloma, two questions must be addressed:

- Is it malignant? If so, is it primary or metastatic cancer?
- Is it functional (ie, is it secreting hormones)?

■ BENIGN OR MALIGNANT?

The two major predictors of malignancy are the tumor's size and its features on imaging.

Tumor size

Many experts regard size as an important factor in differentiating benign tumors such as adrenal adenomas and hyperplasias from malignant lesions such as adrenal carcinomas and metastases from other primary sites.^{4,8,9} The larger an adrenal mass, the more likely it is malignant. However, significant overlap exists, and experts disagree about the threshold that should trigger resection of a nonfunctional adrenal tumor: recommendations range from 4 to 6 cm.^{1,3,7,10}

Hamrahian et al (our group),¹¹ in a retrospective review of 299 adrenalectomies in 290 patients and using surgical histopathology as the gold standard, found that even a threshold of 2 cm is not 100% specific in ruling out malignancy. But our data support 6 cm as a reasonable threshold for surgical resection once radiologic characteristics are taken into account.

Many experts also believe that if an adrenal mass does not grow over time, it can reliably be assumed to be benign.⁷ Only very rarely do masses that do not change in appearance on CT for up to 18 months turn out to be metastases.¹² On the other hand, 5% to 25% of nonfunctioning adrenal masses grow at least 1 cm over time.^{7,13}

Features on imaging studies

The noncontrast CT attenuation coefficient, expressed in Hounsfield units (HU), is increasingly used to differentiate benign adrenal adenomas and hyperplasias from malignant lesions and pheochromocytomas (FIGURE 1). Water has a value of 0; substances that are less dense than water have negative values while substances that are more dense have positive values. Adipose tissue has a relatively low value, so the lesser the fat content, the higher the attenuation coefficient. Intracytoplasmic fat is often abundant in adrenal adenomas but is rare in adrenal metastases, pheochromocytomas, and adrenal cortical carcinomas.¹⁴ Therefore, masses with higher values are more likely to be nonadenomas.

Suggested threshold values range from 0 to 20 HU. A consensus panel of the National Institutes of Health recommended 10 HU,⁷ a threshold value that our group found to be

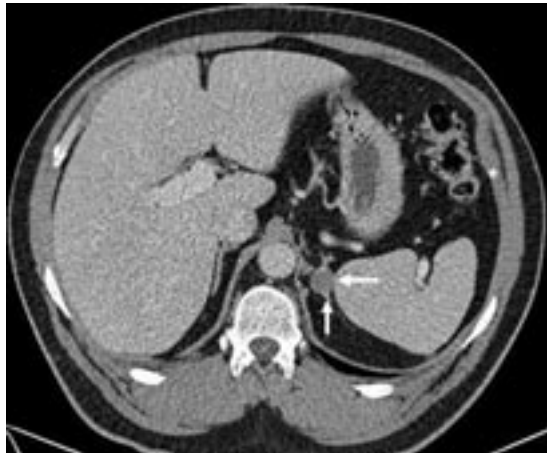

FIGURE 1. Noncontrast CT scan image of a left adrenal mass with attenuation of -10 Hounsfield units, consistent with a benign adenoma.

100% specific for ruling out nonadenomas in our study,¹¹ which contained the largest body of published data with surgical histopathology as the diagnostic gold standard. In addition, we and others have found the HU value on noncontrast CT to be a better criterion than tumor size for distinguishing adrenal adenomas from nonadenomas.^{11,15,16}

Enhancement washout is valuable in differentiating lipid-poor adrenal adenomas (noncontrast HU > 10) from nonadenomas. A CT scan with contrast is performed, the attenuation coefficient of the mass is measured 1 minute after contrast administration and again 15 minutes after contrast administration, and the percentage of enhancement washout is calculated. An absolute enhancement washout percentage of less than 60% at 15 minutes after giving contrast strongly suggests a nonadenoma.^{17,18}

CT characteristics other than lipid content may help differentiate adrenal adenomas from nonadenomas: benign lesions tend to have a smooth border, be round or oval in shape, have sharp margins, conform to the shape of the adrenal gland, contain no calcification within or on the edge of the tumor, be homogeneous, and not enhance after contrast. Although these features can help in characterizing a mass and deciding how to manage it, none of them individually enables one to rule out malignancy confidently.¹⁴

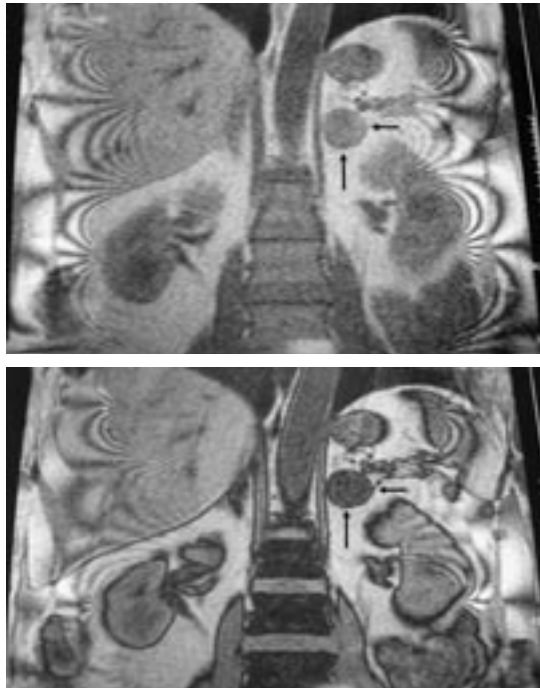


FIGURE 2. In-phase (top) and out-of-phase (bottom) coronal MRI images in a patient with a left adrenal mass. The reduced signal intensity is due to high lipid content and is consistent with adenoma or hyperplasia.

MRI is as effective as CT in differentiating benign from malignant adrenal masses, but it has no clear advantage over CT except in pregnant women, children, and patients with allergies to contrast.¹⁹ On T1-weighted gradient echo images, a drop in signal intensity during “opposed-phase” (out-of-phase) images compared with in-phase images is consistent with high fat content and is highly specific for adrenal adenoma (FIGURE 2).²⁰

Pheochromocytomas can be identified by a very high signal intensity on T2-weighted images, along with no signal loss on opposed-phase vs in-phase T1-weighted images (sensitivity 93%–100%, specificity 88%–98%).^{21–23}

Adrenal scintigraphy using iodomethylnorcholesterol I 131 (NP-59) may also help differentiate benign from malignant adrenal masses larger than 2 cm. Adrenal nonadenomas have no uptake or significantly less uptake than adenomas.²⁴ However, this test is not widely available and takes 5 to 7 days to complete, limiting its usefulness.¹⁸

All adrenal carcinomas and metastases have HU > 10

Positron emission tomography using fluoro-deoxyglucose F 18 may also help differentiate malignant from benign adrenal lesions in patients with proven or suspected malignancy. The test is nearly 100% sensitive and 94% to 95% specific.²⁵ Because it is expensive and not widely available, it is not recommended for routine evaluation of adrenal incidentalomas.

Fine-needle aspiration biopsy

Cytologic study of a specimen obtained by imaging-guided fine-needle aspiration may help in evaluating an adrenal mass suspected of being metastatic that has a noncontrast CT attenuation value of more than 10 HU. It cannot, however, always differentiate an adrenocortical carcinoma from an adrenal adenoma.

To avoid causing a possible hypertensive crisis, pheochromocytoma should always be excluded before fine-needle aspiration of an adrenal mass is attempted.

■ IS IT FUNCTIONAL?

From 6% to 20% of patients with adrenal incidentalomas have hormonal abnormalities,^{2,3,26,27} showing that the mass is functional. Hormonal hypersecretion is most likely with masses that are at least 3 cm in diameter, and it occurs mostly within the first 3 years after diagnosis.¹³

A careful personal and family history, review of systems, and physical examination should be performed in all patients. In addition, patients should be evaluated—at a minimum—for the following conditions:

- Pheochromocytoma
- Cushing syndrome (including subclinical disease)
- Primary aldosteronism (only if hypertensive).

Pheochromocytoma

Up to 11% of adrenal incidentalomas are pheochromocytomas.^{5,28} Screening for pheochromocytoma is mandatory in all cases because of this condition's high rates of morbidity and mortality, as well as because of its unpredictable course. It is completely asymptomatic in up to 15% of cases.^{29,30}

An appropriate initial screening test is

measurement of plasma free metanephrines or 24-hour urine metanephrines. Clinicians should be familiar with the diagnostic characteristics of the assay they use.

Measurement of plasma free metanephrines is 99% sensitive for sporadic cases of pheochromocytoma, so from a practical standpoint, a normal value rules it out.³¹ But this test has a false-positive rate of 10% to 15%, so a positive result warrants either further testing of 24-hour urine metanephrines or a clonidine suppression test, depending on the clinical picture.³²

Cushing syndrome

Most patients with autonomous cortisol-secreting cortical adenomas do not have the typical signs and symptoms of Cushing syndrome. However, from 5% to 20% of patients with adrenal incidentalomas are reported to have subclinical Cushing syndrome. The estimate varies greatly, depending on diagnostic criteria and screening methods,^{5,6,27,33–35} since subclinical Cushing syndrome is still poorly defined. These patients are reported to have an increased frequency of hypertension, glucose intolerance, diabetes, and possibly osteopenia compared with the general population.

In 2002, a National Institutes of Health consensus panel recommended a 1-mg overnight dexamethasone suppression test for initial biochemical evaluation of adrenal incidentalomas. In this test, dexamethasone 1 mg is given at 11 PM and the cortisol level is measured at 8 AM; a normal result is less than 5.0 µg/dL of cortisol. We agree with this recommendation, but with a lower threshold: we would recommend further workup if the dexamethasone challenge does not suppress the patient's cortisol level to less than 1.8 µg/dL.^{7,36} At this level, the main value of the test is to rule out Cushing syndrome, but a positive test does not confirm the diagnosis because false-positives do occur.

An apparent lack of suppression can be caused by a number of interfering conditions, including:

- Decreased dexamethasone absorption
- Drugs that enhance hepatic dexamethasone metabolism (barbiturates, phenytoin, carbamazepine, rifampicin)

Always rule out pheochromocytoma before fine-needle aspiration of an adrenal mass

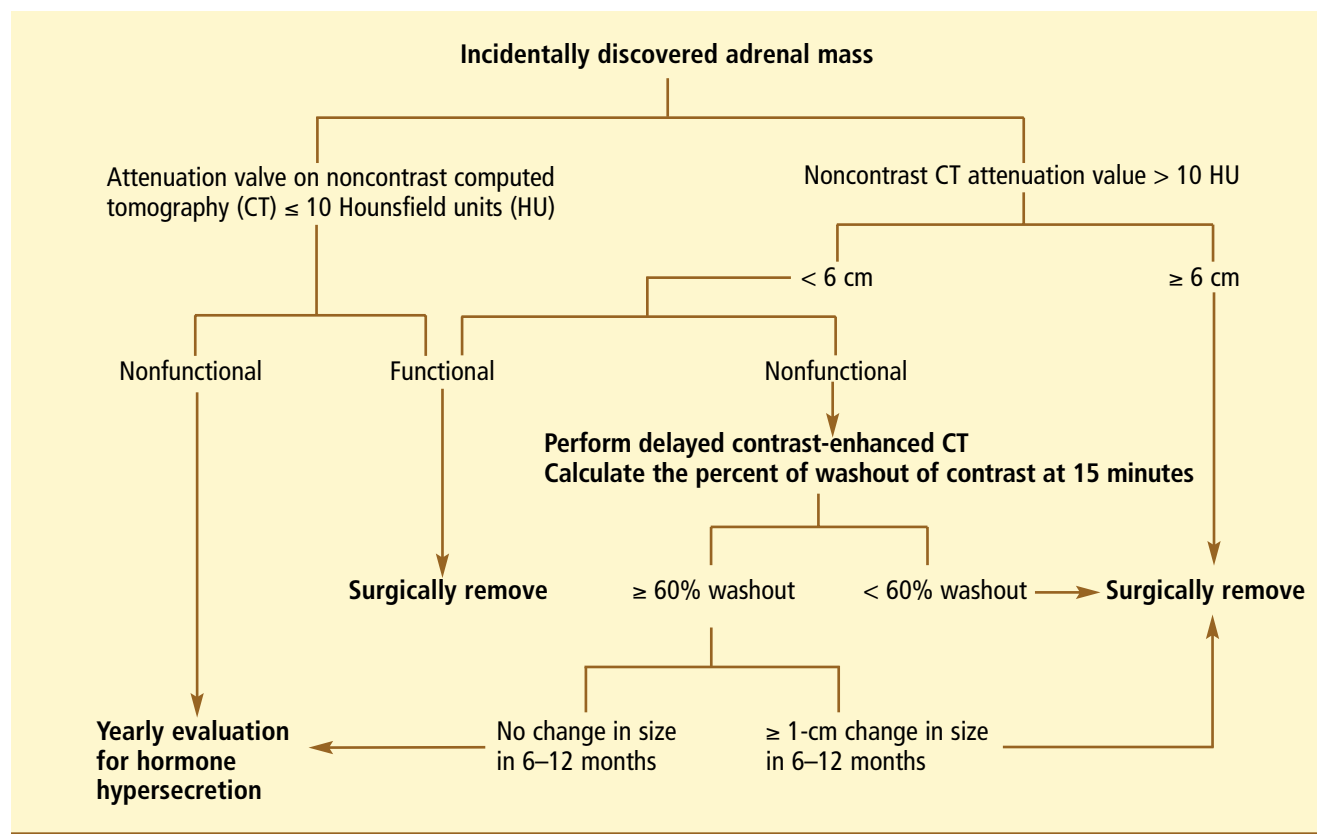


FIGURE 3. Algorithm for managing patients with adrenal incidentaloma.

- Increased concentration of corticosteroid-binding globulin (from estrogens or pregnancy)
- Pseudo-Cushing states.

Estimating the plasma concentration of dexamethasone may be useful in special situations to ensure that an adequate level of dexamethasone is present, but it is not indicated for routine testing.

To diagnose subclinical Cushing syndrome, a reasonable approach is to require at least two of the following abnormal results of tests of the hypothalamo-pituitary-adrenal axis⁴:

- Lack of cortisol suppression during a 1-mg overnight dexamethasone suppression test
- Increased urinary free cortisol levels
- Loss of diurnal cortisol rhythm
- Low or suppressed corticotropin (ACTH) level
- Impaired ACTH response to corticotropin-releasing hormone.

The midnight salivary cortisol level is another helpful test.

Primary aldosteronism

From 1.6% to 3.8% of adrenal incidentalomas are aldosterone-secreting adenomas.^{5,28} Only patients with hypertension should be evaluated for primary aldosteronism.

Hypokalemia in a patient with hypertension suggests aldosteronism, but normokalemia does not exclude it.

The best screening test is the ratio of the ambulatory plasma aldosterone concentration to the plasma renin activity. Plasma should be sampled in the morning. The test can be done in patients taking any antihypertensive medications except spironolactone or eplerenone. A ratio of 20 or greater along with a plasma aldosterone concentration above 10 ng/dL needs to be further evaluated by measuring 24-hour urine aldosterone during salt loading.³³

A very low plasma renin activity level using a highly sensitive assay can result in an

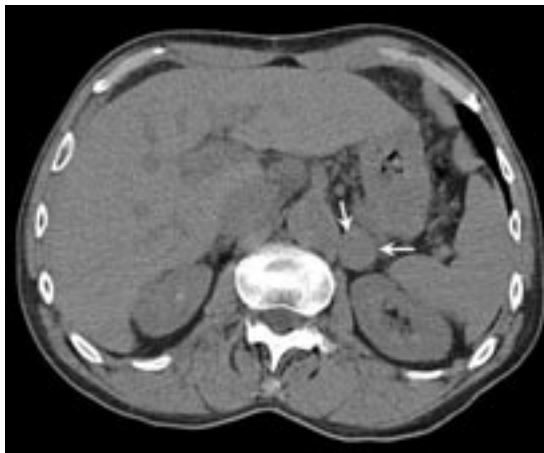

FIGURE 4. Noncontrast CT image of a left adrenal mass measuring 2.2 x 1.3 cm. The mass has an attenuation value of 40 HU, indicating low fat content; therefore, contrast enhancement washout should be measured.

elevated ratio, even if aldosterone is in the low normal range. Changes in position, diuretic therapy, and serum aldosterone levels may also affect the ratio.

Laboratories that use the direct renin assay should use a different ratio as a criterion because direct renin level is about 8 times higher than plasma renin activity.

Androgen-secreting tumors

Isolated androgen-secreting adrenal adenomas are rare, but levels of androgens or their precursors may be high in patients with adrenocortical carcinoma. Patients usually have symptoms related to hormonal hypersecretion, so screening for sex-hormone excess is unnecessary if clinical features are absent. Women with an adrenal mass and physical findings suggestive of hyperandrogenism should have their total testosterone and dehydroepiandrosterone sulfate levels measured.⁷

■ CASE REVISITED

Our patient undergoes hormonal evaluation. The results are as follows:

- Plasma free metanephrines < 0.20 nmol/L (normal < 0.50)
- Plasma free normetanephrines 0.37 nmol/L (normal < 0.90)
- 8 AM serum cortisol after 1-mg dexa-

methasone suppression 2.4 µg/dL (normal < 1.8)

- Plasma aldosterone 7.1 ng/dL (normal 4.5–35.4)
- Plasma renin, direct 11.7 µU/mL (normal 2.4–29).

Because the overnight dexamethasone suppression test is abnormal, he undergoes further testing for subclinical Cushing syndrome. His findings are as follows:

- 24-hour urine free cortisol 18.7 µg/24 hours (normal 20–100)
- Morning plasma ACTH 23 pg/mL (normal 5–50)
- Midnight salivary cortisol 15 ng/dL (normal < 100).

Because the tests of the hypothalamo-pituitary-adrenal axis are normal, we conclude that the initial abnormal 1-mg overnight dexamethasone suppression test was likely falsely positive. The patient is scheduled for follow-up in 6 months.

■ OUR ALGORITHM

Our approach to evaluating adrenal incidentalomas is shown in **FIGURE 3**.

If the noncontrast CT attenuation value is 10 HU or less and the mass is nonfunctional, we do not routinely obtain any follow-up imaging study. However, annual evaluation for hormonal hypersecretion is recommended, especially if the mass is larger than 3 cm.^{13,37} How long follow-up should continue is unknown, and further long-term studies are needed to determine this. The incidence of new hormonal hypersecretion may plateau after 5 years.¹³ The likelihood of primary adrenocortical carcinoma developing from an adenomatous or hyperplastic adrenal mass is not known, but it seems to be extremely rare.^{13,38,39}

If the noncontrast CT attenuation value is greater than 10 HU and the mass measures 6 cm or more, we would refer the patient for surgery. For smaller nonfunctional masses, we obtain the enhancement washout percentage at 15 minutes: if less than 60%, we also refer the patient for surgery. However, this recommendation needs to be further evaluated and confirmed in large studies. If the enhancement washout is 60% or more, patients should have

If the mass is functional or malignant, we usually refer for surgery




a follow-up imaging study in 6 to 12 months and have the mass resected if it grows by more than 1 cm. No good evidence supports continuing radiologic surveillance if the first follow-up study shows no change in tumor size.⁷

If the mass is either functional or malignant, patients are usually referred for surgery. But medical therapy may be acceptable for primary aldosteronism that is secondary to adrenocortical adenoma or hyperplasia. Also, surgery is usually not indicated if malignancy is widespread; any surgical intervention should be pursued only if the patient would benefit.

Compared with open adrenalectomy, laparoscopic surgery results in less postoperative pain, a quicker return of bowel function, a shorter hospital stay, and earlier return to work.⁴⁰ Surgeons who are more experienced tend to obtain better results.

■ CASE CONCLUDED

Our patient has a repeat CT scan (with and without contrast) after 6 months, which shows a nodule in the left adrenal gland measuring 2.2 by 1.3 cm, unchanged in size. On the precontrast scan, the mean attenuation value is 40 HU (**FIGURE 4**). However, 2 minutes after he receives intravenous contrast, the attenuation value is 96 HU and at 15 minutes it is 51. This represents an 80% enhancement washout, suggestive of a lipid-poor adrenal adenoma.

The patient is determined to have an adrenal mass that is hormonally silent with no change in size on 6-month follow-up and with CT characteristics of a benign tumor. He is advised to return in 1 year for evaluation of hormonal hypersecretion. 

■ REFERENCES

1. **Angeli A, Osella G, Ali A, Terzolo M.** Adrenal incidentaloma: an overview of clinical and epidemiological data from the National Italian Study Group. *Horm Res* 1997; 47:279–283.
2. **Barzon L, Sonino N, Fallo F, Palu G, Boscaro M.** Prevalence and natural history of adrenal incidentalomas. *Eur J Endocrinol* 2003; 149:273–285.
3. **Herrera MF, Grant CS, van Heerden JA, Sheedy PF, Ilstrup DM.** Incidentally discovered adrenal tumors: an institutional perspective. *Surgery* 1991; 110:1014–1021.
4. **Mantero F, Terzolo M, Arnaldi G, et al.** A survey on adrenal incidentaloma in Italy. Study group on adrenal tumors of the Italian Society of Endocrinology. *J Clin Endocrinol Metab* 2000; 85:637–644.
5. National Institutes of Health state-of-the-science conference statement. Management of the clinically inapparent adrenal mass (incidentaloma). February 4–6, 2002. http://consensus.nih.gov/ta/021/021_statement.htm.
6. **Kloos RT, Gross MD, Francis IR, Korobkin M, Shapiro B.** Incidentally discovered adrenal masses. *Endocr Rev* 1995; 16:460–484.
7. **Grumbach MM, Biller BM, Braunstein GD, et al.** Management of the clinically inapparent adrenal mass (“incidentaloma”). *Ann Intern Med* 2003; 138:424–429.
8. **Guerrero LA.** Diagnostic and therapeutic approach to incidental adrenal mass. *Urology* 1985; 26:435–440.
9. **Arnaldi G, Masini AM, Giacchetti G, Taccaliti A, Falloia E, Mantero F.** Adrenal incidentaloma. *Braz J Med Biol Res* 2000; 33:1177–1189.
10. **Terzolo M, Ali A, Osella G, Mazza E.** Prevalence of adrenal carcinoma among incidentally discovered adrenal masses. A retrospective study from 1989 to 1994. Gruppo Piemontese Incidentalomi Surrenalici. *Arch Surg* 1997; 132:914–919.
11. **Hamrahan AH, Ioachimescu AG, Remer EM, et al.** Clinical utility of noncontrast computed tomography attenuation value (Hounsfield units) to differentiate adrenal adenomas/hyperplasias from nonadenomas: Cleveland Clinic experience. *J Clin Endocrinol Metab* 2005; 90:871–877.
12. **Singer AA, Obuchowski NA, Einstein DM, Paushter DM.** Metastasis or adenoma? Computed tomographic evaluation of the adrenal mass. *Cleve Clin J Med* 1994; 61:200–205.
13. **Barzon L, Scaroni C, Sonino N, Fallo F, Paoletta A, Boscaro M.** Risk factors and long-term follow-up of adrenal incidentalomas. *J Clin Endocrinol Metab* 1999; 84:520–526.
14. **Boland GW, Lee MJ, Gazelle GS, Halpern EF, McNicholas MM, Mueller PR.** Characterization of adrenal masses using unenhanced CT: an analysis of the CT literature. *AJR Am J Roentgenol* 1998; 171:201–204.
15. **Korobkin M, Brodeur FJ, Yutzy GG, et al.** Differentiation of adrenal adenomas from nonadenomas using CT attenuation values. *AJR Am J Roentgenol* 1996; 166:531–536.
16. **Lee MJ, Hahn PF, Papanicolaou N, et al.** Benign and malignant adrenal masses: CT distinction with attenuation coefficients, size, and observer analysis. *Radiology* 1991; 179:415–418.
17. **Korobkin M, Brodeur FJ, Francis IR, Quint LE, Dunnick NR, Londy F.** CT time-attenuation washout curves of adrenal adenomas and nonadenomas. *AJR Am J Roentgenol* 1998; 170:747–752.
18. **Szolar DH, Korobkin M, Reittner P, et al.** Adrenocortical carcinomas and adrenal pheochromocytomas: mass and enhancement loss evaluation at delayed contrast-enhanced CT. *Radiology* 2005; 234:479–485.
19. **Lockhart ME, Smith JK, Kenney PJ.** Imaging of adrenal masses. *Eur J Radiol* 2002; 41:95–112.
20. **Lee MJ, Mayo-Smith WW, Hahn PF, et al.** State-of-the-art MR imaging of the adrenal gland. *Radiographics* 1994; 14:1015–1029.
21. **Fassnacht M, Kenn W, Allolio B.** Adrenal tumors: How to establish malignancy? *J Endocrinol Invest* 2004; 27:387–399.
22. **Honigschnabl S, Gallo S, Niederle B, et al.** How accurate is MR imaging in characterization of adrenal masses: update of a long-term study. *Eur J Radiol* 2002; 41:113–122.
23. **Heinz-Peer G, Honigschnabl S, Schneider B, Niederle B, Kaserer K, Lechner G.** Characterization of adrenal masses using MR imaging with histopathologic correlation. *AJR Am J Roentgenol* 1999; 173:15–22.
24. **Gross MD, Shapiro B, Francis IR, et al.** Scintigraphic evaluation of clinically silent adrenal masses. *J Nucl Med* 1994; 35:1145–1152.
25. **Boland GW, Goldberg MA, Lee MJ, et al.** Indeterminate adrenal mass in patients with cancer: evaluation at PET with 2-[F-18]-fluoro-2-deoxy-D-glucose. *Radiology* 1995; 194:131–134.
26. **Mantero F, Masini AM, Opocher G, Giovagnetti M, Arnaldi G.** Adrenal incidentaloma: an overview of hormonal data from the National Italian Study Group. *Horm Res* 1997; 47:284–289.
27. **Osella G, Terzolo M, Borretta G, et al.** Endocrine evaluation of incidentally discovered adrenal masses (incidentalomas). *J Clin Endocrinol Metab* 1994; 79:1532–1539.




28. **Mansmann G, Lau J, Balk E, Rothberg M, Miyachi Y, Bornstein SR.** The clinically inapparent adrenal mass: update in diagnosis and management. *Endocr Rev* 2004; 25:309–340.
29. **Bravo EL.** Pheochromocytoma: current perspectives in the pathogenesis, diagnosis, and management. *Arq Bras Endocrinol Metabol* 2004; 48:746–50. Epub 2005 Mar 7.
30. **Kudva YC, Young WF Jr, Thompson GB.** Adrenal incidentaloma: an important component of the clinical presentation spectrum of benign sporadic adrenal pheochromocytoma. *Endocrinologist* 1999; 9:77–84.
31. **Lenders JW, Pacak K, Walther MM, et al.** Biochemical diagnosis of pheochromocytoma: which test is best? *JAMA* 2002; 287:1427–1434.
32. **Bravo EL, Tagle R.** Pheochromocytoma: state-of-the-art and future prospects. *Endocr Rev* 2003; 24:539–553.
33. **Young WF Jr.** Management approaches to adrenal incidentalomas. A view from Rochester, Minnesota. *Endocrinol Metab Clin North Am* 2000; 29:159–185,x.
34. **Terzolo M, Osella G, Ali A, et al.** Subclinical Cushing's syndrome in adrenal incidentaloma. *Clin Endocrinol (Oxf)* 1998; 48:89–97.
35. **Terzolo M, Bovio S, Reimondo G, et al.** Subclinical Cushing's syndrome in adrenal incidentalomas. *Endocrinol Metab Clin North Am* 2005; 34:423–439,x.
36. **Arnaldi G, Angeli A, Atkinson AB, et al.** Diagnosis and complications of Cushing's syndrome: a consensus statement. *J Clin Endocrinol Metab* 2003; 88:5593–5602.
37. **Barzon L, Fallo F, Sonino N, Boscaro M.** Development of overt Cushing's syndrome in patients with adrenal incidentaloma. *Eur J Endocrinol* 2002; 146:61–66.
38. **Barry MK, van Heerden JA, Farley DR, Grant CS, Thompson GB, Ilstrup DM.** Can adrenal incidentalomas be safely observed? *World J Surg* 1998; 22:599–603.
39. **Hofle G, Gasser RW, Lhotta K, Janetschek G, Kreczy A, Finkentstet G.** Adrenocortical carcinoma evolving after diagnosis of preclinical Cushing's syndrome in an adrenal incidentaloma. A case report. *Horm Res* 1998; 50:237–242.
40. **Filippini S, Guerrieri M, Arnaldi G, et al.** Laparoscopic adrenalectomy: a report on 50 operations. *Eur J Endocrinol* 1998; 138:548–553.

.....
ADDRESS: Amir H. Hamrahian, MD, Department of Endocrinology, Diabetes, and Metabolism, A53, Cleveland Clinic, 9500 Euclid Avenue, Cleveland, OH 44195; e-mail hamraha@ccf.org.

**Visit our web site at
<http://www.ccfm.org>**

.....
**Contact us by e-mail at
ccjm@ccf.org**

Get current on women's health.



Get your copy of the *Cleveland Clinic Journal of Medicine's* new **Special Issue on Women's Health**.

This 104-page compilation of 15 peer-reviewed articles from recent issues of the CCJM will update you on a host of women's health topics, from new guidelines for cervical cancer screening to the current role of hormone therapy to the latest contraceptive options.

Supplies are limited, so get your copy today. Cost is \$18.00 per copy. Send check or money order, payable to *Cleveland Clinic Journal of Medicine*, to:

Cleveland Clinic Journal of Medicine
 Attn: Kathy Dunasky
 9500 Euclid Avenue, NA32
 Cleveland, OH 44195
 Email: dunaskk@ccf.org Phone: 216-445-3605
 Fax: 216-444-9385

Send issue to:

NAME _____

ADDRESS _____

CITY _____

STATE _____ ZIP _____