

## CLINICAL PRACTICE

## Ectopic Pregnancy

Kurt T. Barnhart, M.D., M.S.C.E.

*This Journal feature begins with a case vignette highlighting a common clinical problem. Evidence supporting various strategies is then presented, followed by a review of formal guidelines, when they exist. The article ends with the author's clinical recommendations.*

**A healthy 29-year-old woman who has been trying to conceive presents with vaginal spotting for the past 5 days and intermittent crampy abdominal pain in her left lower quadrant for the past 3 days. Although she normally has regular menstrual cycles, her last menstrual period was 6 weeks and 2 days before presentation. She has had a spontaneous vaginal delivery and an anembryonic gestation treated by dilation and curettage. How should this patient be evaluated and treated?**

## THE CLINICAL PROBLEM

Miscarriage is the most common complication of early pregnancy and occurs in 15 to 20% of clinically evident pregnancies.<sup>1</sup> Ectopic pregnancy, the implantation of a fertilized ovum outside the endometrial cavity, occurs in approximately 1.5 to 2.0% of pregnancies and is potentially life-threatening.<sup>2</sup> The incidence of ectopic pregnancy increased by a factor of six between 1970 and 1992,<sup>2</sup> but it has since remained stable.<sup>3</sup> The associated mortality has decreased markedly to 0.5 deaths per 1000 pregnancies, mainly because of early diagnosis and treatment before rupture.<sup>2</sup> Nevertheless, ruptured ectopic pregnancies continue to occur, often because the clinician or the patient did not recognize the early signs and symptoms of the condition,<sup>4</sup> and such pregnancies account for 6% of all maternal deaths.<sup>5</sup>

Damage to the fallopian tubes from pelvic inflammatory disease, previous tubal surgery, or a previous ectopic pregnancy is strongly associated with an increased risk of ectopic pregnancy.<sup>6,7</sup> Minor risk factors include a history of cigarette smoking, an age over 35 years, and many lifetime sexual partners.<sup>6</sup> There is no clear association between ectopic pregnancy and the use of oral contraceptives, previous elective pregnancy termination, miscarriage, or cesarean section.<sup>6,7</sup> Conception with an intrauterine device in place or after a tubal ligation is rare, but an estimated 25 to 50% of such pregnancies are ectopic.

Women who are subfertile are also at increased risk for an ectopic pregnancy because altered tubal integrity (or function) contributes to both conditions.<sup>8</sup> In addition, the use of assisted reproductive techniques, especially in vitro fertilization, increases the risk of ectopic pregnancy, even among women who do not have damaged fallopian tubes. The risk of heterotopic pregnancy also increases, from 1 case per 4000 women in the general population to 1 case per 100 women who have undergone in vitro fertilization.<sup>9</sup> However, half of all women who receive a diagnosis of an ectopic pregnancy do not have any known risk factors.<sup>7,10</sup>

Ectopic pregnancies that involve implantation in the cervix, the interstitial portion of the fallopian tube, the ovary, the abdomen, or a scar from a cesarean section account for less than 10% of all ectopic pregnancies. These unusual ectopic pregnancies are difficult to diagnose and are associated with high morbidity.

The risk of recurrence of ectopic pregnancy is approximately 10% among women

From the Department of Obstetrics and Gynecology, University of Pennsylvania Medical Center, Philadelphia. Address reprint requests to Dr. Barnhart at the Department of Obstetrics and Gynecology, 3701 Market St., 8th Fl., Philadelphia, PA 19104, or at kbarnhart@obgyn.upenn.edu.

N Engl J Med 2009;361:379-87.

Copyright © 2009 Massachusetts Medical Society.



**An audio version  
of this article  
is available at  
NEJM.org**

with one previous ectopic pregnancy and at least 25% among women with two or more previous ectopic pregnancies.<sup>11</sup> Women in whom the affected fallopian tube has been removed are at increased risk for ectopic pregnancy in the remaining tube. Case series suggest that approximately 60% of women who receive a diagnosis of an ectopic pregnancy are subsequently able to have an intrauterine pregnancy.<sup>11-13</sup>

---

## STRATEGIES AND EVIDENCE

---

### EVALUATION

Patients with a ruptured ectopic pregnancy present with signs of shock, including hypotension, tachycardia, and rebound tenderness, and they should be treated on an emergency basis. However, most patients present before rupture, with nonspecific manifestations that may often occur with a viable intrauterine pregnancy or with miscarriage. These symptoms and signs include first-trimester bleeding (which is typically intermittent, light, and either bright or dark red and which rarely exceeds the normal menstrual flow), crampy abdominal or pelvic pain (which is unilateral or diffuse and ranges from mild to debilitating), or both. Women with these symptoms or signs should be considered to be at risk for ectopic pregnancy until a definitive diagnosis is made. There is no demonstrated medical or economic benefit of screening asymptomatic pregnant women for ectopic pregnancy.<sup>14</sup>

Unruptured ectopic pregnancy can be diagnosed rapidly and accurately with the use of transvaginal ultrasonography in conjunction with a quantitative serum human chorionic gonadotropin (hCG) test. The first step in evaluating a woman who presents in the first trimester of pregnancy with the symptoms described above is to determine whether the gestation is potentially viable; if not, the location of the pregnancy should be determined. Ultimately, a growing intrauterine pregnancy, a nonviable intrauterine pregnancy (miscarriage), or an ectopic pregnancy will be diagnosed. Management is drastically different for these three conditions, underscoring the need for a definitive and accurate diagnosis.

### ULTRASONOGRAPHIC EXAMINATION

Understanding ultrasonographic findings that are characteristic of normal and abnormal early gestation facilitates the recognition of ectopic pregnancy<sup>15-24</sup> (Table 1 and Fig. 1). In gestations longer

than 5.5 weeks, a transvaginal ultrasonographic examination should identify an intrauterine pregnancy with almost 100% accuracy.<sup>25-27</sup> The sensitivity of transvaginal ultrasonography for the diagnosis of ectopic pregnancy ranges from 73 to 93% and is dependent on the gestational age and the expertise of the ultrasonographer.<sup>25-27</sup> Four criteria for ultrasonographic examination are used to identify extrauterine gestations, with varying sensitivity and specificity (Table 1). Misdiagnosis can occur when an adnexal mass is not clearly distinct from the ovary or is mistaken for other structures in the pelvis, including the bowel, a simple cyst adjacent to the tube and ovary (a paratubal cyst), an endometrioma, or the corpus luteum.

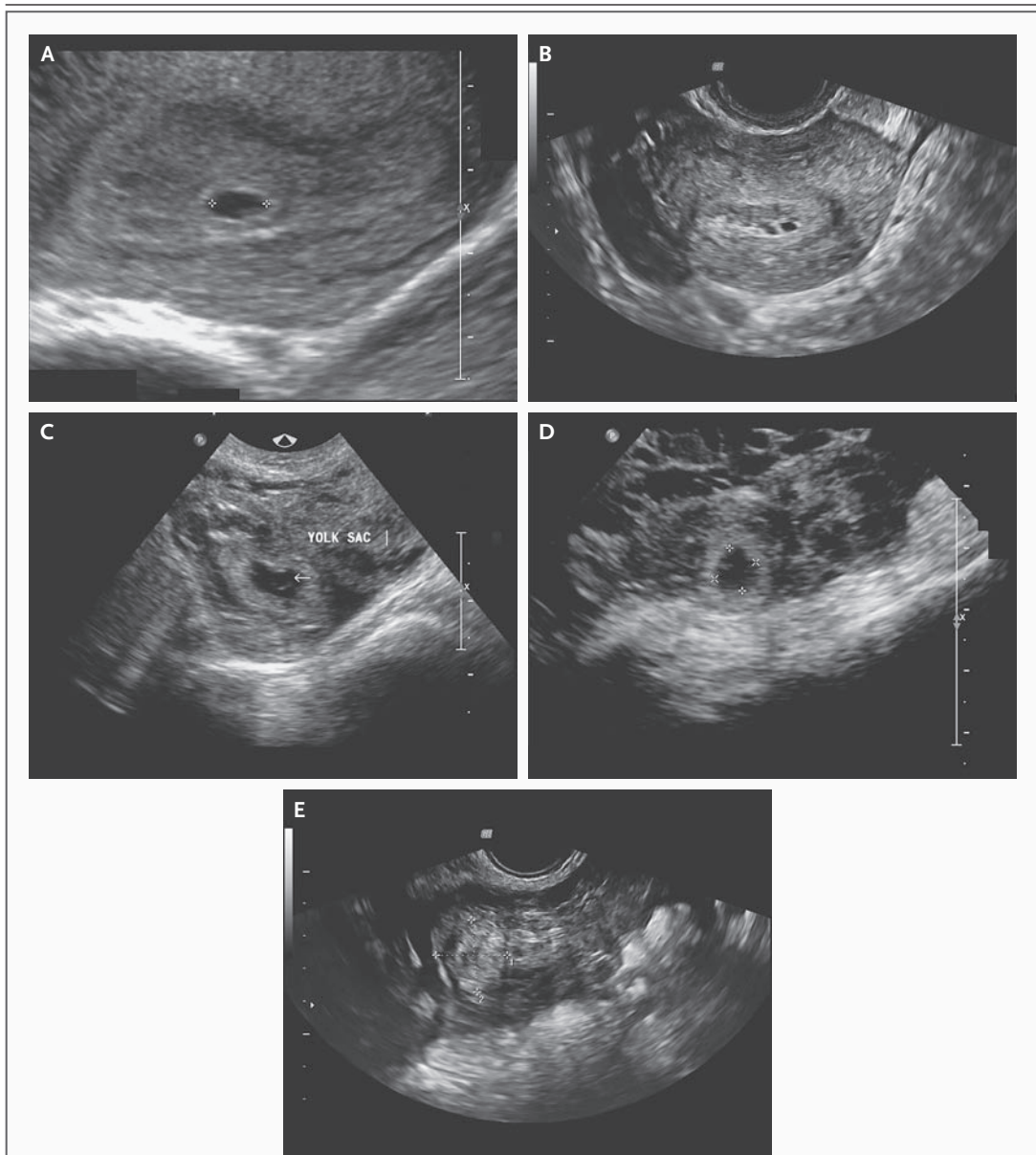
In 8 to 31% of women in whom ectopic pregnancy is suspected, the initial ultrasonographic examination does not show a pregnancy in either the uterus or the fallopian tubes<sup>22,23,27,28</sup> (sometimes called a pregnancy of unknown location). An intrauterine pregnancy may not be visualized because the gestational sac has not yet developed or has collapsed. An early ectopic pregnancy, without any evidence of hemorrhage, may be too small to be detected on ultrasonography. Other reasons for nonvisualization include suboptimal operator expertise or ultrasonographic equipment and the presence of uterine anomalies, fibroids, or a hydrosalpinx, which can mask an intrauterine or extrauterine pregnancy. Approximately 25 to 50% of women with an ectopic pregnancy initially present with a pregnancy of unknown location,<sup>22,28,29</sup> and approximately 7 to 20% of women with a pregnancy of unknown location ultimately receive a diagnosis of an ectopic pregnancy.<sup>22</sup>

### CORRELATION OF ULTRASONOGRAPHIC FINDINGS WITH hCG VALUES

A single serum hCG value neither identifies the presence or absence of an intrauterine or ectopic pregnancy nor predicts rupture, but it can serve as a surrogate marker for gestational age. This value can be used to determine the level of hCG at which the sensitivity of ultrasonography for the detection of intrauterine pregnancy approaches 100% and at which the absence of an intrauterine pregnancy suggests abnormal or ectopic gestation. This "discriminatory hCG value" has been reported to be between 1500 and 3000 mIU per milliliter.<sup>11,30,31</sup> The use of a value at the lower end of the range increases the sensitivity for the diagnosis of an ectopic pregnancy, but it also in-

**Table 1. Useful Ultrasonographic Findings in the Evaluation of Women at Risk for an Ectopic Pregnancy.**

Pregnancy and Gestational Age	Ultrasonographic Findings	Comments	References
Normal intrauterine pregnancy			
Gestational age, 4 to <5 wk from last menstrual period	Eccentrically placed small gestational sac, 0.2 to 0.5 cm in diameter, may be visible within one layer of endometrium		Goldstein and Wolfson <sup>15</sup>
Gestational age, 5 wk from last menstrual period	Double decida sign: two echogenic rings surrounded by intrauterine fluid collection	Needs to be differentiated from a pseudo-sac; sometimes associated with an ectopic pregnancy	Bradley et al. <sup>16</sup>
Gestational age, 5.5 wk from last menstrual period	Yolk sac visualized within the gestational sac	Considered to be definitive confirmation of an intrauterine pregnancy	Rossavik et al. <sup>17</sup>
Gestational age, 6 wk from last menstrual period	An embryonic pole should be visualized		Hadlock et al. <sup>18</sup>
Gestational age, 6.5 wk from last menstrual period	Fetal cardiac activity apparent		Goldstein <sup>19</sup>
Nonviable intrauterine pregnancy			
Anembryonic gestation	Gestational sac with a mean diameter of >2 cm, without evidence of a fetal pole	The gestational sac is often asymmetric	Levi et al. <sup>20</sup>
Embryonic or fetal death	Crown-rump length of >0.5 cm without fetal cardiac activity		Goldstein, <sup>19</sup> Brown et al. <sup>21</sup>
Ectopic (tubal) pregnancy			
Viable extrauterine pregnancy	Extrauterine gestational sac with fetal pole and cardiac activity	Presence of a yolk sac or fetal pole has positive predictive value of almost 100% for identifying ectopic pregnancy	Kirk et al., <sup>22</sup> Condous et al., <sup>23</sup> Brown and Doublet <sup>24</sup>
Nonviable extrauterine gestation	Extrauterine gestational sac with a fetal pole, without cardiac activity	Fetal pole with or without cardiac activity seen in 13% of ectopic pregnancies diagnosed by ultrasonography	Levi et al., <sup>20</sup> Kirk et al., <sup>22</sup> Condous et al. <sup>23</sup>
Ring sign	Adnexal mass with a hyperechoic ring around a gestational sac	Seen in 20% of ectopic pregnancies diagnosed by ultrasonography	Levi et al., <sup>20</sup> Kirk et al., <sup>22</sup> Condous et al. <sup>23</sup>
Nonhomogeneous mass	Adnexal mass separate from the ovary	Seen in 60% of ectopic pregnancies diagnosed by ultrasonography; positive predictive value ranges from 80 to 90%	Levi et al., <sup>20</sup> Kirk et al., <sup>22</sup> Condous et al. <sup>23</sup>



**Figure 1. Ultrasonographic Scans in Patients at Risk for Ectopic Pregnancy.**

Panel A shows the early gestational sac in the uterus without a yolk sac or fetal pole in an intrauterine pregnancy. The gestational sac has a diameter of 0.65 cm and is consistent with a gestational age of 5 weeks 2 days. Panels B through E show ectopic pregnancies. Panel B shows a pseudo-gestational sac that resembles the gestational sac in Panel A, but it is centrally located, it is not symmetric, and it is associated with septation. Panel C shows a gestational sac and a yolk sac with evidence of associated free fluid. Panel D shows a ring sign — a hyperechoic ring around an extrauterine gestational sac. Panel E shows an ectopic pregnancy characterized by an extrauterine adnexal mass, separate from the ovary, without any evidence of a gestational sac. The mass is 2.2 by 2.2 cm. (Courtesy of Eileen Wang, M.D., University of Pennsylvania, Philadelphia.)

creases the false positive rate, with the attendant risk of interrupting a normal gestation by surgical or medical intervention. The use of a higher discriminatory value increases the specificity.

The accuracy of ultrasonographic findings in making a diagnosis in a woman at risk for an ectopic pregnancy varies according to the serum hCG level.<sup>22</sup> In one study, when the hCG value was

below 1500 mIU per milliliter, the positive predictive value of ultrasonographic testing for the diagnosis of intrauterine pregnancy was only 80% and the positive predictive value for the diagnosis of ectopic pregnancy was 60%.<sup>29</sup>

Serial measurement of serum hCG values can help to distinguish among a potentially viable intrauterine gestation, a resolving spontaneous abortion, and an ectopic pregnancy (Table 2). Approximately 99% of viable intrauterine pregnancies are associated with an increase in hCG levels of at least 53% in 2 days; this is a slower increase in the hCG level than the 66% increase reported previously.<sup>32,34</sup> The rate of increase in the level of hCG is similar in multiple and single gestations, but the absolute hCG value is higher at a given gestational age in multiple gestation.<sup>35</sup> The rate of decrease of serial hCG values among women who ultimately receive a diagnosis of a miscarriage depends on the initial hCG value, with slower decreases when initial hCG values are lower<sup>33</sup> (Table 2). When hCG values decrease at a rate that is at least as high as that expected in a spontaneous miscarriage, continued outpatient surveillance is warranted until levels are undetectable. Approximately 50% of women with an ectopic pregnancy present with increasing hCG levels, and 50% present with decreasing hCG values.<sup>36</sup> However, 71% of women who receive a diagnosis of an ectopic pregnancy have serial serum hCG values that increase more slowly than would be expected with a viable intrauterine pregnancy or decrease more slowly than would be expected with a miscarriage (Fig. 2).<sup>36,37</sup>

When the hCG level is well above the discriminatory value, efforts should be made to establish the location of a pregnancy that has been deemed nonviable because of failure to visualize an intrauterine pregnancy on ultrasonography.<sup>11,23,37</sup> A decrease in the hCG level of 20% or more, 12 to 24 hours after uterine evacuation, suggests that trophoblastic cells were probably removed from the uterus (i.e., that there was a nonviable intrauterine gestation). A postoperative plateau or increase in the hCG value strongly suggests an ectopic pregnancy. A patient with a decrease in the hCG level can be monitored with serial hCG measurements until levels are undetectable, or until pathological evaluation of the curettage specimen shows chorionic villi. In one series involving 111 women with nonviable pregnancies of unknown location who underwent uterine evac-

**Table 2. Expected Change in Serum hCG Levels in First Week of Monitoring Women at Risk for Ectopic Pregnancy.**

Type of Pregnancy	Change in hCG	
	After 2 days	After 7 days
	<i>percent</i>	
Growing intrauterine pregnancy*		
In 50% of women	124	500
In 85% of women	63	256
In 99% of women	53	133
Spontaneous abortion†		
Initial hCG, 50 mIU/ml	-12	-34
Initial hCG, 500 mIU/ml	-21	-60
Initial hCG, 2000 mIU/ml	-31	-79
Initial hCG, 5000 mIU/ml	-35	-84

\* Data are from Barnhart et al.<sup>32</sup>

† This change occurred in 90% of women with spontaneous abortion. Data are from Barnhart et al.<sup>33</sup>

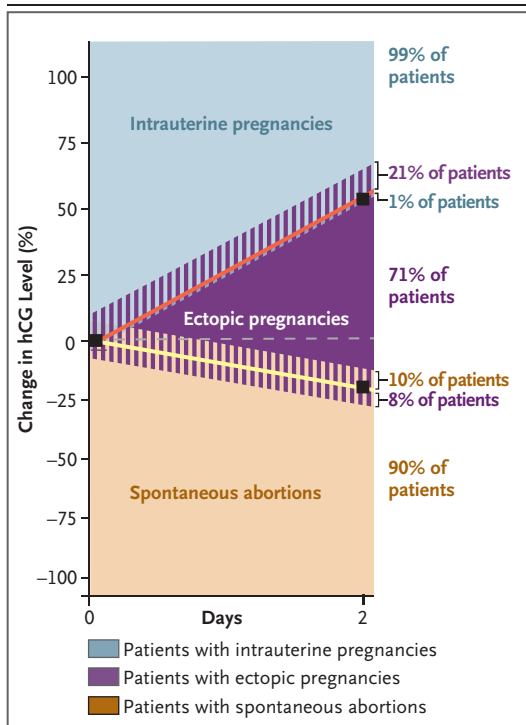
uation, intrauterine chorionic villi were detected in 37% of the women overall and in 51% of the women with initial hCG values that were more than 1500 mIU per milliliter; these findings ruled out ectopic pregnancy.<sup>38</sup>

A repeat ultrasonographic examination 2 to 7 days after presentation may identify the location of a pregnancy that was not identified on initial ultrasonographic examination. Case reports suggest that the follow-up ultrasonographic examination in patients with indeterminate initial results will identify 90% of ectopic pregnancies within 7 days after presentation.<sup>22,39</sup> However, the concern is that a delay in the diagnosis of ectopic pregnancy might result in rupture.

In women in whom hCG levels are decreasing, serial hCG measurements should be performed until hCG is no longer detectable in the serum; this may take up to 6 weeks. Women in whom an intrauterine gestation has not been confirmed remain at risk for rupture of an ectopic pregnancy until there is no detectable hCG.<sup>25</sup> In patients with hCG levels that are increasing, ultrasonographic examination should be performed, or repeated, when levels have risen above the discriminatory value.

Decision rules based on the first two serum hCG levels (measured 48 hours apart),<sup>40,41</sup> a scoring system (based on age, the presence or absence of vaginal bleeding, previous miscarriage or ecto-





**Figure 2. Change in the hCG Level in Intrauterine Pregnancy, Ectopic Pregnancy, and Spontaneous Abortion.**

An increase or decrease in the serial human chorionic gonadotropin (hCG) level in a woman with an ectopic pregnancy is outside the range expected for that of a woman with a growing intrauterine pregnancy or a spontaneous abortion 71% of the time. However, the increase in the hCG level in a woman with an ectopic pregnancy can mimic that of a growing intrauterine pregnancy 21% of the time, and the decrease in the hCG level can mimic that of a spontaneous abortion 8% of the time.

pic pregnancy, and the initial hCG level),<sup>42</sup> and a single measurement of the serum progesterone level<sup>43</sup> have each been reported to be ultimately predictive of the pregnancy location. However, the sensitivity and specificity of these methods are not sufficiently high to obviate further testing and observation.

#### MANAGEMENT

Treatment of an ectopic pregnancy can be surgical or medical. Surgical treatment may involve removing the affected fallopian tube (salpingectomy) or dissecting the ectopic pregnancy with conservation of the tube (salpingostomy). Laparoscopy is cost-effective and is the preferred surgical

approach.<sup>12,13</sup> Laparotomy is reserved for patients with extensive intraperitoneal bleeding, intravascular compromise, or poor visualization of the pelvis at the time of laparoscopy.

Observational studies indicate that among women treated with salpingostomy as compared with those treated with salpingectomy, rates of subsequent intrauterine pregnancy are higher (73% vs. 57%) but that rates of subsequent ectopic pregnancy are also higher (15% vs. 10%).<sup>11-13</sup> Postoperative serial monitoring of hCG values is required after salpingostomy because trophoblastic cells remain in the fallopian tube in 5 to 20% of women. When a persistent ectopic pregnancy is identified, it may be managed with surgical removal or with adjuvant methotrexate.<sup>44</sup> The decision to perform a salpingostomy or salpingectomy is often made intraoperatively on the basis of the extent of damage to the affected and contralateral tubes, but it is also dependent on the patient's history of ectopic pregnancy and wish for future fertility, the availability of assisted reproductive technology, and the skill of the surgeon.

#### MEDICAL MANAGEMENT

Medical management of ectopic pregnancy with intramuscular administration of the folic acid antagonist methotrexate is a commonly used and safe alternative to surgical management.<sup>45-47</sup> Single-dose, two-dose, and multidose regimens are named for the intended number of doses, rather than the actual number of doses given. Treatment protocols for methotrexate therapy are shown in Table 1 of the Supplementary Appendix, available with the full text of this article at NEJM.org.

As compared with the multidose regimen, the single-dose regimen is more commonly used and requires fewer visits, but it is associated with a higher rate of treatment failure. A meta-analysis of nonrandomized studies showed success rates of 93% (95% confidence interval [CI], 89 to 96) for multidose therapy and 88% (95% CI, 86 to 90) for single-dose therapy.<sup>48</sup> The odds ratio for failure of single-dose therapy as compared with multidose therapy was 2.0 (95% CI, 1.1 to 3.6;  $P=0.03$ ) after adjustment for the hCG value and 4.8 (95% CI, 1.8 to 12.6) after additional adjustment for the presence or absence of fetal cardiac activity. A single small, randomized trial also showed a lower success rate with single-dose therapy than with multidose therapy (89% vs.

93%), but the difference was not significant.<sup>49</sup> The two-dose regimen was designed to increase the likelihood of successful therapy without more visits than are required with a single-dose regimen, but it has not been directly compared with the other regimens.<sup>46</sup> Factors that are associated with failure of medical management include initial hCG values greater than 5000 mIU per milliliter,<sup>50</sup> ultrasonographic detection of a moderate or large amount of free peritoneal fluid, the presence of fetal cardiac activity, and a pretreatment increase in the serum hCG level of more than 50% over a 48-hour period.

Medical management of a presumed ectopic pregnancy should be avoided when miscarriage has not been ruled out, since it may result in unnecessary chemotherapy for a completed miscarriage,<sup>51</sup> and it results in more visits per patient without cost savings or a reduction in complication rates.<sup>52</sup> The lack of a definite diagnosis also compromises counseling regarding future fertility and the risk of ectopic pregnancy.

**SURGICAL VERSUS MEDICAL THERAPY**

Randomized trials comparing medical therapy with laparoscopic salpingostomy for the treat-

ment of an unruptured ectopic pregnancy have shown a nonsignificantly higher success rate with multidose methotrexate (relative success rate, 1.8; 95% CI, 0.73 to 4.6) and a significantly lower success rate with single-dose methotrexate (relative success rate, 0.82; 95% CI, 0.72 to 0.94), as compared with salpingostomy.<sup>12,13</sup> A cost-effectiveness analysis showed that systemic methotrexate therapy is less costly than laparoscopic surgical therapy only if the diagnosis of ectopic pregnancy does not require laparoscopy and if serum hCG values are greater than 1500 mIU per milliliter.<sup>53</sup> Observational studies suggest that rates of tubal patency (62 to 90%) and recurrence of ectopic pregnancy (8 to 15%) are similar after medical and surgical treatment.<sup>12,13</sup>

Some ectopic pregnancies resolve spontaneously without therapy. Although case series have suggested rates of resolution as high as 70%, these rates are derived from selected cases of early tubal gestations with hCG values that were below 1000 mIU per milliliter and were decreasing.<sup>54</sup> Women who are offered the option of expectant management (i.e., watchful waiting) must be informed of the potential risk of tubal rupture despite decreasing hCG values.

**Table 3. Contraindications to Medical Management of Ectopic Pregnancy with Systemic Methotrexate.\***

Contraindication	ACOG†	ASRM‡
Absolute contraindications	Breast-feeding; laboratory evidence of immunodeficiency; preexisting blood dyscrasias (bone marrow hypoplasia, leukopenia, thrombocytopenia, or clinically significant anemia); known sensitivity to methotrexate; active pulmonary disease; peptic ulcer disease; hepatic, renal, or hematologic dysfunction; alcoholism; alcoholic or other chronic liver disease	Breast-feeding; evidence of immunodeficiency; moderate-to-severe anemia, leukopenia, or thrombocytopenia; sensitivity to methotrexate; active pulmonary or peptic ulcer disease; clinically important hepatic or renal dysfunction; intrauterine pregnancy
Relative contraindications	Ectopic mass >3.5 cm; embryonic cardiac motion	Ectopic mass >4 cm detected by transvaginal ultrasonography; embryonic cardiac activity detected by transvaginal ultrasonography; patient declines blood transfusion; patient is not able to participate in follow-up; high initial hCG level (>5000 mIU/ml)
Choice of regimen based on hCG level	Multidose regimen of methotrexate may be appropriate if presenting hCG value >5000 mIU/ml	Single-dose regimen of methotrexate better in patients with a low initial hCG level

\* ACOG denotes American College of Obstetricians and Gynecologists, and ASRM American Society for Reproductive Medicine.

† Data are from the American College of Obstetricians and Gynecologists.<sup>10</sup>

‡ Data are from the Practice Committee of the American Society for Reproductive Medicine.<sup>51</sup>

## AREAS OF UNCERTAINTY

Data from randomized trials are lacking to inform the optimal management of ectopic pregnancy (surgical vs. medical) with respect to recurrence rates or the potential for future fertility. Data from randomized trials comparing the outcomes of salpingostomy with those of salpingectomy are also lacking. There is no consensus on a threshold value of hCG above which methotrexate is contraindicated or the preferred protocol when methotrexate is used. One systematic review concluded that the rate of success of methotrexate therapy is significantly lower when the hCG value is above 5000 mIU per milliliter,<sup>50</sup> whereas another review concluded that a multi-dose methotrexate regimen should be used only in patients with initial serum hCG values of less than 3000 mIU per milliliter and that single-dose methotrexate can be considered in patients with initial hCG values below 1500 mIU per milliliter.<sup>12</sup>

## GUIDELINES

The American College of Obstetricians and Gynecologists and the American Society for Reproductive Medicine have published guidelines for the medical management of ectopic pregnancy.<sup>10,51</sup> There is a consensus regarding the need for a definitive diagnosis before treatment, the approach

to the pretreatment evaluation, general contraindications to medical treatment, and the association between higher hCG values and an increased risk of treatment failure (Table 3).

## CONCLUSIONS AND RECOMMENDATIONS

The patient described in the vignette has signs and symptoms of an ectopic pregnancy; these clinical manifestations are nonspecific, and many patients have no known risk factors. In patients with vaginal bleeding or pain and detectable levels of hCG, pelvic ultrasonographic examination should be performed to look for an intrauterine or extrauterine gestation. When findings are nondiagnostic, serial quantitative hCG tests and repeat ultrasonographic examination are useful in determining potential viability. Ultrasonographic evaluation, uterine evacuation, or laparoscopy can be used to confirm the location of the pregnancy. If the diagnosis of ectopic pregnancy is made early, conservative surgical treatment (salpingostomy or salpingectomy) or medical therapy with methotrexate will avert complications, including rupture, emergency surgery, and associated illness and death.

Supported by a grant (R01 HD36455) from the National Institutes of Health.

No potential conflict of interest relevant to this article was reported.

## REFERENCES

1. Wilcox AJ, Weinberg CR, O'Connor JF, et al. Incidence of early loss of pregnancy. *N Engl J Med* 1988;319:189-94.
2. Chang J, Elam-Evans LD, Berg CJ, et al. Pregnancy related mortality surveillance — United States, 1991–1999. *MMWR Surveill Summ* 2003;52:1-9.
3. Van Den Eeden SK, Shan J, Bruce C, Glasser M. Ectopic pregnancy rate and treatment utilization in a large managed care organization. *Obstet Gynecol* 2005;105:1052-7.
4. Dorfman SF. Deaths from ectopic pregnancy, United States, 1979 to 1980. *Obstet Gynecol* 1983;62:334-8.
5. Ectopic pregnancy — United States, 1990–1992. *MMWR Morb Mortal Wkly Rep* 1995;44:46-8.
6. Ankum WM, Mol BW, van der Veen F, Bossuyt PM. Risk factors for ectopic pregnancy: a meta-analysis. *Fertil Steril* 1996;65:1093-9.
7. Barnhart KT, Sammel MD, Gracia CR, Chittams J, Hummel AC, Shaunik A. Risk factors for ectopic pregnancy in women with symptomatic first-trimester pregnancies. *Fertil Steril* 2006;86:36-43.
8. Clayton HB, Schieve LA, Peterson HB, Jamieson DJ, Reynolds MA, Wright VC. Ectopic pregnancy risk with assisted reproductive technology procedures. *Obstet Gynecol* 2006;107:595-604.
9. Maymon R, Shulman A. Controversies and problems in the current management of tubal pregnancy. *Hum Reprod Update* 1996;2:541-51.
10. ACOG Practice Bulletin no. 94: medical management of ectopic pregnancy. *Obstet Gynecol* 2008;111:1479-85.
11. Seeber BE, Barnhart KT. Suspected ectopic pregnancy. *Obstet Gynecol* 2006;107:399-43. [Erratum, *Obstet Gynecol* 2006;107:955.]
12. Mol F, Mol BW, Ankum WM, van der Veen F, Hajenius PJ. Current evidence on surgery, systemic methotrexate and expectant management in the treatment of tubal ectopic pregnancy: a systematic review and meta-analysis. *Hum Reprod Update* 2008;14:309-19.
13. Hajenius PJ, Mol F, Mol BW, Bossuyt PM, Ankum WM, van der Veen F. Interventions for tubal ectopic pregnancy. *Cochrane Database Syst Rev* 2007;24:CD000324.
14. Mol BW, van der Veen F, Bossuyt PM. Symptom-free women at increased risk of ectopic pregnancy: should we screen? *Acta Obstet Gynecol Scand* 2002;81:661-72.
15. Goldstein SR, Wolfson R. Endovaginal ultrasonographic measurement of early embryonic size as a means of assessing gestational age. *J Ultrasound Med* 1994;13:27-31.
16. Bradley WG, Fiske CE, Filly RA. The double sac sign of early intrauterine pregnancy: use in exclusion of ectopic pregnancy. *Radiology* 1982;143:223-6.
17. Rossavik IK, Torjusen GO, Gibbons WE. Conceptual age and ultrasound measurements of gestational sac and crown-rump length in in vitro fertilization pregnancies. *Fertil Steril* 1988;49:1012-7.
18. Hadlock FP, Shah YP, Kanon DJ, Lind-



- sey JV. Fetal crown-rump length: reevaluation of relation to menstrual age (5-18 weeks) with high-resolution real-time US. *Radiology* 1992;182:501-5.
19. Goldstein SR. Significance of cardiac activity on endovaginal ultrasound in very early embryos. *Obstet Gynecol* 1992;80:670-2.
20. Levi CS, Lyons EA, Zheng XH, Lindsay DJ, Holt SC. Endovaginal US: demonstration of cardiac activity in embryos of less than 5.0 mm in crown-rump length. *Radiology* 1990;176:71-4.
21. Brown DL, Emerson DS, Felker RE, Cartier MS, Smith WC. Diagnosis of early embryonic demise by endovaginal sonography. *J Ultrasound Med* 1990;9:631-6.
22. Kirk E, Papageorgiou AT, Condous G, Tan L, Bora S, Bourne T. The diagnostic effectiveness of an initial transvaginal scan in detecting ectopic pregnancy. *Hum Reprod* 2007;22:2824-8.
23. Condous G, Okaro E, Khalid A, et al. The accuracy of transvaginal ultrasonography for the diagnosis of ectopic pregnancy prior to surgery. *Hum Reprod* 2005;20:1404-9.
24. Brown DL, Doubilet PM. Transvaginal sonography for diagnosing ectopic pregnancy: positivity criteria and performance characteristics. *J Ultrasound Med* 1994;13:259-66.
25. Barnhart K, Mennuti MT, Benjamin I, Jacobson S, Goodman D, Coutifaris C. Prompt diagnosis of ectopic pregnancy in an emergency department setting. *Obstet Gynecol* 1994;84:1010-5.
26. Shalev E, Yarom I, Bustan M, Weiner E, Ben-Shlomo I. Transvaginal sonography as the ultimate diagnostic tool for the management of ectopic pregnancy: experience with 840 cases. *Fertil Steril* 1998;69:62-5.
27. Condous G, Lu C, Van Huffel S, Timmerman D, Bourne T. Human chorionic gonadotrophin and progesterone levels for the investigation of pregnancies of unknown location. *Int J Gynaecol Obstet* 2004;86:351-7.
28. Banerjee S, Aslam N, Zosmer N, Woelfer B, Jurkovic D. The expectant management of women with pregnancies of unknown location. *Ultrasound Obstet Gynecol* 1999;14:231-6.
29. Barnhart KT, Simhan H, Kamelle SA. Diagnostic accuracy of ultrasound above and below the beta-hCG discriminatory zone. *Obstet Gynecol* 1999;94:583-7.
30. Romero R, Kadar N, Jeanty P, et al. Diagnosis of ectopic pregnancy: value of the discriminatory human chorionic gonadotropin zone. *Obstet Gynecol* 1985;66:357-60.
31. Cacciatore B, Stenman UH, Ylöstalo P. Diagnosis of ectopic pregnancy by vaginal ultrasonography in combination with a discriminatory serum hCG level of 1000 IU/L (IRP). *Br J Obstet Gynaecol* 1990;97:904-8.
32. Barnhart KT, Sammel MD, Rinaudo PF, Zhou L, Hummel AC, Guo W. Symptomatic patients with an early viable intrauterine pregnancy: HCG curves redefined. *Obstet Gynecol* 2004;104:50-5.
33. Barnhart K, Sammel MD, Chung K, Zhou L, Hummel AC, Guo W. Decline of serum human chorionic gonadotropin and spontaneous complete abortion: defining the normal curve. *Obstet Gynecol* 2004;104:975-81.
34. Kadar N, Caldwell BV, Romero R. A method of screening for ectopic pregnancy and its indications. *Obstet Gynecol* 1981;58:162-6.
35. Chung K, Sammel MD, Coutifaris C, et al. Defining the rise of serum HCG in viable pregnancies achieved through use of IVF. *Hum Reprod* 2006;21:823-8.
36. Silva C, Sammel MD, Zhou L, Gracia C, Hummel AC, Barnhart K. Human chorionic gonadotropin profile for women with ectopic pregnancy. *Obstet Gynecol* 2006;107:605-10.
37. Seeber BE, Sammel MD, Guo W, Zhou L, Hummel A, Barnhart KT. Application of redefined human chorionic gonadotropin curves for the diagnosis of women at risk for ectopic pregnancy. *Fertil Steril* 2006;86:454-9.
38. Barnhart KT, Katz I, Hummel A, Gracia CR. Presumed diagnosis of ectopic pregnancy. *Obstet Gynecol* 2002;100:505-10.
39. Condous G, Kirk E, Lu C, et al. There is no role for uterine curettage in the contemporary diagnostic workup of women with a pregnancy of unknown location. *Hum Reprod* 2006;21:2706-10.
40. Condous G, Okaro E, Khalid A, et al. The use of a new logistic regression model for predicting the outcome of pregnancies of unknown location. *Hum Reprod* 2004;19:1900-10.
41. Kirk E, Condous G, Haider Z, et al. The practical application of a mathematical model to predict the outcome of pregnancies of unknown location. *Ultrasound Obstet Gynecol* 2006;27:311-5.
42. Barnhart KT, Casanova B, Sammel MD, Timbers K, Chung K, Kulp JL. Prediction of location of a symptomatic early gestation based solely on clinical presentation. *Obstet Gynecol* 2008;112:1319-25.
43. Mol BW, Lijmer JG, Ankum W, van der Veen F, Bossuyt PMM. The accuracy of single serum progesterone measurement in the diagnosis of ectopic pregnancy: a meta-analysis. *Hum Reprod* 1998;13:3220-7.
44. Seifer DB, Gutman JN, Grant WD, Kamps CA, DeCherney AH. Comparison of persistent ectopic pregnancy after laparoscopic salpingostomy versus salpingectomy at laparotomy for ectopic pregnancy. *Obstet Gynecol* 1993;81:378-82.
45. Stovall TG, Ling FW. Single-dose methotrexate: an expanded clinical trial. *Am J Obstet Gynecol* 1993;168:1759-65.
46. Barnhart K, Hummel AC, Sammel MD, Menon S, Jain JK, Chakhtoura NA. Use of "2-dose" regimen of methotrexate to treat ectopic pregnancy. *Fertil Steril* 2007;87:250-6.
47. Stovall TG, Ling FW, Buster JE. Outpatient chemotherapy of unruptured ectopic pregnancy. *Fertil Steril* 1989;51:435-8.
48. Barnhart KT, Gosman G, Ashby R, Sammel M. The medical management of ectopic pregnancy: a meta-analysis comparing "single dose" and "multidose" regimens. *Obstet Gynecol* 2003;101:778-84.
49. Alleyassin A, Khademi A, Aghahosseini M, Safdarian L, Badenoosh B, Hamed EA. Comparison of success rates in the medical management of ectopic pregnancy with single-dose and multiple-dose administration of methotrexate: a prospective, randomized clinical trial. *Fertil Steril* 2006;85:1661-6.
50. Menon S, Collins J, Barnhart KT. Establishing a human chorionic gonadotropin cutoff to guide methotrexate treatment of ectopic pregnancy: a systematic review. *Fertil Steril* 2007;87:481-4.
51. Practice Committee of the American Society for Reproductive Medicine. Medical treatment of ectopic pregnancy. *Fertil Steril* 2006;86:Suppl:S96-S102.
52. Ailawadi M, Lorch SA, Barnhart KT. Cost effectiveness of presumptively medically treating women at risk for ectopic pregnancy compared to first performing a dilatation and curettage. *Fertil Steril* 2005;83:376-82.
53. Mol BWJ, Hajenius PJ, Engelsbel S, et al. Treatment of tubal pregnancy in the Netherlands: an economic comparison of systemic methotrexate administration and laparoscopic salpingostomy. *Am J Obstet Gynecol* 1999;181:945-51.
54. Ylöstalo P, Cacciatore B, Koskimies A, et al. Conservative treatment of ectopic pregnancy. *Ann N Y Acad Sci* 1991;626:516-23.

Copyright © 2009 Massachusetts Medical Society.